

Minimally Invasive Surgical Procedures for Patients with Advanced and Recurrent Ovarian Cancer

Samir A. Farghaly

*The Joan and Sanford I. Weill/ The Graduate School of Medical Sciences
and The New York Presbyterian Hospital -
Weill Cornell Medical Center, Cornell University, New York, NY
USA*

1. Introduction

Estimated, 225,000 new cases of ovarian cancer in the world in 2011, with approximately 140,000 deaths. In the United States of America, ovarian cancer is the second most gynecological cancer. It is the most common cause of gynecological cancer related death primarily because most patients present with advanced disease. 65-70% of patients are diagnosed at an advanced stage, conferring a 5-year survival rate of 30-55%. Epithelial ovarian cancer (EOC) remains the most lethal gynecologic cancer in the United States. In 2010, approximately 21,880 new cases and 13,850 deaths occurred. There is no proven screening test for this disease. Many women present with vague symptoms, including abdominal bloating, change in bowel or bladder habits, early satiety, or abdominal pain. It is diagnosed at advanced stage for about 75% of patients [1]. It spreads along the peritoneal surfaces to the upper abdomen by direct extension or by peritoneal implantation [2]. Metastases to the diaphragm, especially to the right hemi-diaphragm, are common in patients with advanced ovarian cancer. About 40% of patients with advanced ovarian cancer present with bulky metastatic diaphragmatic disease. About 19% of patients are diagnosed with International Federation of Obstetrics and Gynecology (FIGO) [Table 1.] stage I disease, in which the tumor is confined to one or both ovaries. (1). Stage I disease is usually diagnosed incidentally during laparoscopic or laparotomy surgery for benign-looking ovarian tumors, but, following complete staging, it is upstaged in 30% of patients due to microscopic metastatic disease.(2,3). FIGO guidelines have stated that the standard management for apparent early-stage disease is complete surgical staging, including total abdominal hysterectomy, bilateral salpingo-oophorectomy, pelvic and para-aortic lymph node dissection, infracolic omentectomy, multiple peritoneal washing, and multiple peritoneal biopsies (4). Initial evaluation includes a thorough history and physical examination, imaging studies such as MRI and computerized tomography scanning, assessment of tumor markers such as CA-125, biopsies, cystoscopy and colonoscopy. The standard treatment for primary ovarian cancer consists of maximum cytoreductive effort to reduce residual tumor (RT), followed by platinum-based chemotherapy (3, 4). It has been shown that cytoreduction has a more significant influence on survival than the extent of a

metastatic disease observed before surgery (5). This target has value in the primary cytoreduction (3), and in interval debulking surgery after neoadjuvant chemotherapy (6), in addition to in secondary cytoreduction in platinum-sensitive recurrent ovarian cancer patients (7). Extensive upper abdominal debulking surgery increases the rate of optimal cytoreduction and it is related with improved survival rates in advanced ovarian cancer undergoing primary cytoreduction and interval debulking surgery (8). Hepatic resection (9), splenectomy (10) and (11), video-assisted thoracic surgery (12), and diaphragmatic resection (13), (14), (15), (16), (17), (18) and (19) have been considered as components of primary cytoreduction when necessary.

Stage I: Growth limited to the ovaries
IA Growth limited to one ovary: no ascites present containing malignant cells. No tumor on the external surface; capsule intact.
IB Growth limited to both ovaries: no ascites present containing malignant cells. No tumor on the external surfaces; capsules intact.
IC* Tumor either stage IA or IB, but with tumor on surface of one or both ovaries, or with capsule ruptured, or with ascites present containing malignant cells, or with positive peritoneal washings.
Stage II: Growth involving one or both ovaries with pelvic extension.
IIA Extension and/or metastases to the uterus and/or tubes.
IIB Extension to other pelvic tissues.
IIC* Tumor either stage IIA or IIB, but with tumor on surface of one or both ovaries, or with capsule(s) ruptured, or with ascites present containing malignant cells, or with positive peritoneal washings.
Stage III: Tumor involving one or both ovaries with histologically confirmed peritoneal implants outside the pelvis and/or positive retroperitoneal or inguinal nodes. Superficial liver metastases equals stage III. Tumor is limited to the true pelvis but with histologically proven malignant extension to small bowel or omentum.
IIIA Tumor grossly limited to the true pelvis, with negative nodes, but with histologically confirmed microscopic seeding of abdominal peritoneal surfaces, or histologic proven extension to small bowel or mesentery.
IIIB Tumor of one or both ovaries with histologically confirmed implants, peritoneal metastasis of abdominal peritoneal surfaces, none exceeding 2 cm in diameter; nodes are negative.
IIIC Peritoneal metastasis beyond the pelvis > 2 cm in diameter and/or positive retroperitoneal or inguinal nodes.
Stage IV: Growth involving one or both ovaries with distant metastases. If pleural effusion is present, there must be positive cytology to allot a case to stage IV. Parenchymal liver metastasis equals stage IV.
* In order to evaluate the impact on prognosis of the different criteria for allotting cases to stage IC or IIC, it would be of value to know if rupture of the capsule was spontaneous, or caused by the surgeon; and if the source of malignant cells detected peritoneal washings, or ascites.

Table 1. Carcinoma of the ovary: figo classification (rio de janerio 1988)

2. Minimally invasive surgery in advanced ovarian cancer

Laparoscopic assisted surgery can be utilized in the surgical management of apparent early-stage ovarian cancer, in assessing resectability of advanced disease prior to laparotomy, and also in second-look procedures.

Several studies showed that laparoscopy is safe and feasible in the surgical management of apparent early-stage ovarian cancer. (20-23) In a Study comparing laparoscopic treatment of gynecologic malignancies with traditional laparotomy for early-stage ovarian cancer, it was observed (24) that the acceptable survival rates with decreased morbidity and shorter hospitalization: 91.6% with disease-free survival and overall survival of 100% at 46 months. The advantages of laparoscopy are faster recovery with early return of bowel function and a shorter hospital stay. Laparoscopy can be useful, when deciding whether to proceed with primary cytoreductive surgery or neoadjuvant chemotherapy in advanced epithelial ovarian cancer. In a study of 87 patients who underwent diagnostic laparoscopy, 53 were considered resectable.(25). Of these 53 patients, 96% were optimally cytoreduced. Laparoscopy seems to be an acceptable method for assessing disease resectability. Operative time of 120 to 240 minutes has been reported with laparoscopic staging of ovarian cancer (26). Surgical complications could include vascular and gastrointestinal injuries, and possibly port site metastases (27). There is a concern that ovarian cancer mass may rupture while trying to remove it. Ovarian cyst rupture has been reported in 12% to 25% of patients undergoing laparoscopy(28,29) and rupture may cause intra-abdominal dissemination. Several studies have suggested that cyst rupture increase recurrence rate and decrease survival (30,31). To avoid any spillage, the ovarian mass should be placed in a laparoscopic bag and retrieved through the umbilical port or through a colpotomy. Minimally invasive robot- assisted laparoscopic surgery, utilizing da Vinci surgical system (Figures 1 and 2), has been employed to duplicate traditional open procedures via small incisions in the skin with surgical outcomes equivalent or superior to a traditional surgical approach. Robotic surgery enables the operator to control the robotic system alone and to perform more precise and complex operations. The da Vinci Surgical System provides surgeons with 1) intuitive translation of the instrument handle to the tip movement, thus eliminating the mirror-image effect, 2) visualization with high quality 3-dimensional images and stable camera platform, 3) scaling, 4) tremor filtering, 5) coaxial alignment of eyes, hand, and tooltip images, 6) EndoWrist with a 360-degree range of motion, 7) comfortable, ergonomically ideal operating position.




Fig. 1. Da Vinci Surgical System

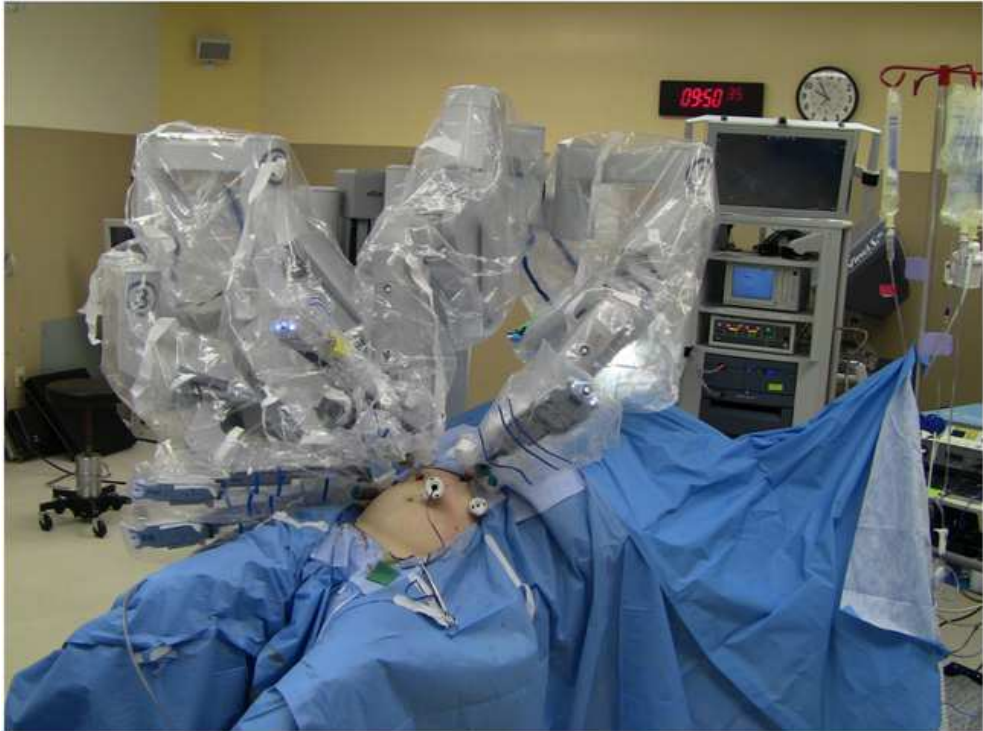

Fig. 2. Robotic platform docked off patient's right shoulder in 10 degree reverse Trendelenburg position, and 10 degree rotation to left.

It has been demonstrated that minimally invasive surgery is associated with less blood loss, shorter hospital stay, less post operative pain, improved cosmesis, and faster recovery compared to traditional approaches (32), (33). 10 cases were reported with an operative time of 207 minutes, blood loss of 355 cc and nodal yield of 27 (34). It was observed that the operative time in robotic radical hysterectomy was 241 minutes and blood loss of 71 cc, and no conversion to laparotomy reported (35).

3. Laparoscopic assesment of disease extent and potential for resectability

Staging laparoscopy (S-LPS) has been shown to predict optimal cytoreduction in primary and recurrent ovarian cancer (36), (37), (38), (39). It has been shown that an objective evaluation of the complete debulking is available for primary advanced cases utilizing a laparoscopic predictive index score (40- 41). In addition, the inclusion of S-LPS can reduce the risk of explorative laparotomies to about 10%, with respect to 20% and 30% obtained with the classical criteria of evaluation of response. S-LPS could increase optimal cytoreduction in 20% of patients with stable disease. The explanation to this, could be the presence of radiological artifacts due to the effects of chemotherapy, such as adhesions or fibrosis secondary to tumor shrinkage, which would probably alter the diagnostic performances of conventional images. The laparoscopic predictive score of surgical outcome

has been shown to be reliable in selected group of patients (41-42). The laparoscopic parameters meeting the inclusion criteria have been mesenteral retraction, bowel and stomach infiltration, and superficial liver metastases. Excluding bowel infiltration, these results confirmed others (43-44). It is clear that, S-LPS has an important role in the prediction of optimal cytoreduction in advanced ovarian cancer patients at primary diagnosis.

4. Laparoscopic re-assessment and 2nd look surgery

Second-look surgical reassessments in patients with advanced ovarian cancer have been performed to identify patients who had a complete pathologic response to chemotherapy, as demonstrated by numerous biopsies that were negative for persistent cancer. . The surgical method involved a laparotomy with extensive exploration of the abdomen, including multiple peritoneal washings, multiple biopsies, and, more than often, additional retroperitoneal lymph node sampling (45). With the current chemotherapy regimens, 75 - 80% of patients with optimally cytoreduced disease have a complete clinical response to primary chemotherapy, but only 50% of these patients are found to have a negative second look (46),(47). About one-half of all patients, who achieve a negative second look develop recurrent disease. It has been shown that, there is no survival benefit to the second-look procedure (48-51). Laparoscopy had been used to perform second-look evaluations in patients with ovarian cancer. Initial studies of second look by laparoscopy reported inadequate visualization; a high false-negative rate of between 11 and 55%; a high rate of complications, primarily bowel injuries, of 2 to 9%; and a higher recurrence rate following negative second-look laparoscopy (52 -55). More recent studies, however, have shown that laparoscopic second-look evaluations are equivalent to those performed by laparotomy, but are associated with significantly lower blood loss, decreased operating time, short hospital stay, and decreased hospital charges (56), (57). The current purpose of laparoscopic second-look surgery is to identify 3 patients categories: (1) those with microscopic diseases, (2) those with resectable disease that can successfully be rendered microscopic, and (3) those with gross, unresectable disease. In general, laparoscopy is an efficient and accurate technique for surgical reassessment following primary therapy in advanced ovarian cancer patients. Despite initial good response rates with primary chemotherapy, the majority of patients with advanced ovarian cancer will die of their disease. As approximately 50% of patients with a pathologically negative second look will eventually suffer from recurrent disease, as these patients all have microscopic disease. Studies have found, that patients with microscopic disease at second-look surgical reassessment have a good prognosis and a 5-year survival rate of 50 to 70% with continued therapy. Furthermore, patients who are successfully cytoreduced to microscopic disease at the time of second look have a prognosis equivalent to those found to have microscopic disease (58-61). Therefore, this group represents a subset of patients who have an overall better prognosis and may potentially be curable with effective therapy. Studies have suggested a potential benefit to consolidation/salvage therapy in this group of patients (62,63). It appears that microscopic disease may be missed by laparoscopy compared with laparotomy, but as all patients in this group (both negative-second-look and microscopically positive second-look patients) may benefit from consolidation therapy, the small advantage of a more accurate diagnosis of microscopic disease does not warrant laparotomy. It has been shown that, the rate of positive retroperitoneal nodes as the only evidence of disease at second look was only 3.8% (64). Several studies have shown that second-look laparoscopy was considered a promising

candidate to replace second-look laparotomy which has been considered as standard treatment (65-67). In most initial studies which were conducted involving a small number of patients, second look laparoscopy did not produce satisfactory results and inappropriate operative field was reported to reach up to 12% and resulted in a false negative rate between 29.1% and 55% (65,68,69). It has been shown that patients in complete remission after chemotherapy underwent laparotomy and histological examination right after suspicious lesions were detected by second-look laparoscopy. As a result, the positive and negative predictive values of laparoscopy were 100% (six of six cases) and 86% (two false-negative out of 14 cases), respectively. Thorough observation of intraperitoneal lesions was available in 95% of patients in the LT group and only in 41% of patients in the LPS group due to intraperitoneal adhesions after previous surgeries. Though this study has some limitations in which postoperative survival rates were not compared with the results of the operation, it suggested that second look laparoscopy was less reliable than second-look laparotomy (67). Russo reported similar results (70). In a retrospective study by Husain on 150 cases of second look laparoscopy (71), the procedure was reported to be safe and accurate as a second-look operation. Also, the authors observed that the complication rates were reportedly low when laparoscopy was performed on patients who had received a primary debulking operation, and the recurrence rates of laparoscopic second-look in patients with histologically negative findings and a negative predictive value were also reported to be equivalent to those in patients who underwent laparotomic second-look (71). Second-look laparoscopy is thought to have disadvantages including limited access to lesions due to adhesions formed after previous surgeries, inappropriate operative fields and difficulty in manual examination of lesions. However, it has several advantages to offset these disadvantages. These are:

1. When using second-look laparoscopy not for removal of lesions but for diagnosis, the preoperative imaging procedure enables the extent and duration of operation to be predicted equivalently to those in non-invasive surgery,
2. Enlarged laparoscopic images enable the detection of minute lesions,
3. A certain degree of adhesion due to previous surgeries does not affect the performance of experienced laparoscopists (76), (77).

Currently, advanced laparoscopic procedures are increasingly being utilized as an alternative to laparotomy in gynecological surgery.(72-74). A meta-analysis of 27 prospective randomized trials has proven the benefits of laparoscopic compared with abdominal gynecologic surgery: decreased pain, decreased surgical-site infections (decreased relative risk 80%), decreased hospital stay (2 days less), quicker return to activity (2 weeks sooner), and fewer postoperative adhesions (decreased 60%).(75)

5. Minimally invasive thoracic surgery for patients with advanced ovarian cancer

In advanced and recurrent ovarian cancer, the presence of macroscopic intrathoracic disease may alter patient management, particularly if less than 1–2 cm intrathoracic tumor deposits. That would leave the patient with suboptimal residual disease at the conclusion of maximum intra-abdominal cytoreduction. It has been reported that rate of optimal primary debulking ranges from 27% to 51% (78), (79) and (80). The benefits of debulking in patients with malignant pleural effusions compared with other stage IV disease criteria have been

evaluated. In a study of 84 patients with stage IV disease, including 38% of those patients with malignant pleural effusions, in a study it was reported a median survival of 38.4 months in optimally debulked patients (≤ 1 cm) and 10.3 months for patients with suboptimal residual disease ($P = 0.0004$) (79). On univariate analysis, there was no difference in median survival comparing patients with pleural effusion and other stage IV criteria. Although several retrospective reviews have demonstrated a survival benefit to optimal intra-abdominal debulking in patients with malignant pleural effusions, these patients still have decreased survival when compared with patients who have disease confined to the abdomen. Evaluating optimally cytoreduced stage IIIC and stage IV patients, it has been reported (82) reported a median survival of 58 months for patients who had stage IIIC disease and 30 months for patients with stage IV disease ($p = 0.016$). In patients with symptomatic malignant pleural effusions, video-assisted thoracic surgery (VATS) provides therapeutic benefits, as thoracoscopic pleurodesis is an effective technique for performing pleurodesis, particularly when using talc as the sclerosant. It was observed that the use of more extensive ablative techniques and radical upper abdominal procedures is required to achieve optimal cytoreduction (83). The involvement of the diaphragm in patients with ovarian cancer is the limiting factor preventing optimal cytoreduction (84). Diaphragmatic superficial tumor studding can be ablated or resected using diaphragmatic peritonectomy. Several authors have described the use of extensive diaphragmatic resections for full thickness or deeply invasive diaphragmatic disease (85, (86). VATS may be helpful in evaluating the extent of superficial and full thickness diaphragmatic disease and can then be used to plan appropriate intra-abdominal surgical approaches. In patients with isolated pleural-based disease, VATS can also facilitate intrathoracic cytoreduction. The outcomes of 30 patients who underwent thoracoscopy either by a transdiaphragmatic approach at laparotomy was observed, or through the chest wall prior to a planned abdominal procedure (81). In this series, 33% (10/30) underwent pleural implant ablation and/or tumor excision, which influenced the final cytoreductive outcome (87). VATS should be considered for incorporation into the standard management algorithm for patients with advanced ovarian cancer and pleural effusion. The rate of pleural involvement is underestimated in patients with advanced ovarian cancer. Preoperative computed tomography (CT) identified only one third of patients who had macroscopic pleural nodules by video-assisted thoracoscopy (VAT) (88). Occult pleural involvement may be present in up to 84% of patients with abdominal diaphragmatic involvement. (89). Without routine pleural exploration, failure to remove thoracic lesions occurs in up to one third of patients (89). It has been reported that VAT is feasible and safe in patients with advanced ovarian cancer (87). Pleural metastases are common in patients with ovarian malignancies and pleural effusions. Previously reported rates range from 42% to 65%, Video-assisted thoracoscopy is better than CT for evaluating pleural involvement. In a retrospective study of 12 patients with large pleural effusions, chest CT detected pleural lesions in only 2 of 6 patients who had pleural disease by VAT.(87).

Routine examination of the pleural cavity may improve staging accuracy, even in patients with limited abdominal involvement. In another study, the result of VAT influenced treatment decisions in 33% of patients, (87).

Pleural involvement has been shown to influence patient outcomes (90). In a retrospective study, median survival after optimal cytoreductive surgery was 58 months in patients with stage IIIC disease and 30 months in those with stage IV disease ($P = 0.016$). This survival

difference may be attributed to residual intrathoracic disease responsible for decreased efficacy of complete abdominal cytoreduction or to tumor aggressiveness in patients with stage IV disease. Extensive thoracic cytoreductive surgery has been suggested in combination with abdominal surgery. It has been reported (91) that performing VAT may translate into therapeutic benefits in 30% of cases. Other studies found better survival in patients who underwent complete cytoreductive surgery (91), (92).

Ovarian cancer usually spreads along different routes: lymphatic, haematogenous and transcaelomic. One of its features is the possible peritoneal and pleural dissemination. Mediastinal lymph node metastasis predicts poor prognosis (93). CPLN colonization is frequently associated with intrathoracic disease, which presents as right-sided pleural effusion. This is explained by the anatomic arrangement of abdominal lymphatic drainage, which follows a clockwise route, involving first the thoracic lymphatic stations on the right side. Metastatic calcification of supradiaphragmatic nodes from ovarian primary, is an interesting phenomenon, and is reported with an incidence up to 35%. Calcified intrathoracic nodes in patients with previous ovarian serous adenocarcinoma cannot be ruled out as granulomatous disease, but metastatic deposits must be excluded. Progressive growth of the involved station will point out to the latter. FDG-PET scan proves to be unreliable because granulomatous lymphadenitis which show an increased FDG-uptake.

Surgery for patients with ovarian cancer is carried to achieve histologic diagnosis, disease staging, and prolonged survival, and Videothoracoscopy is a reliable procedure for that. The minimally invasive approach enables thorough exploration of the entire pleural cavity, easy resection of any small nodes sited within the pericardial fat, and removal of bilateral CPLN growths. Resection of isolated node metastases could improve outlook for slow growing tumors. It has been shown that ovarian tumor growth rate seems a sound parameter (93).

6. Laparoscopic assisted diaphragmatic and hepatic surgery in patients with advanced ovarian cancer

Advanced ovarian cancer spreads along the peritoneal surfaces to the abdomen, and often it involves the upper abdomen by direct extension or by peritoneal implantation. Metastases to the diaphragm, especially to the right hemi-diaphragm, are common in patients with advanced ovarian cancer, and up 40% of patients with advanced ovarian cancer present with bulky metastatic diaphragmatic disease. The current standard treatment for primary ovarian cancer consists of maximum cytoreductive effort to reduce residual tumor (RT), followed by platinum-based chemotherapy (94), (95). It has been observed that cytoreduction has a more significant influence on survival than the extent of a metastatic disease observed before surgery(96); this target has value not only in the primary cytoreduction (94), but also in interval debulking surgery after neoadjuvant chemotherapy (97), and in secondary cytoreduction in platinum-sensitive recurrent ovarian cancer patients (98). It is accepted that upper-abdominal spread of disease represents a major limit to achieve an optimal residual disease after primary cytoreduction (99). Extensive upper abdominal debulking surgery increases the rate of optimal cytoreduction and it is related with improved survival rates in advanced ovarian cancer undergoing primary cytoreduction and interval debulking surgery (100). Thus, hepatic resection(99), splenectomy [102] and [103], video-assisted thoracic surgery [104], and diaphragmatic resection [105], [106], [107], [108], [109], [110] and [111] have been advocated as components

of radical primary cytoreduction. The aim of surgery in advanced or recurrent ovarian cancer patients should be the removal of any macroscopic intra-abdominal disease. It has been shown (94) that each decrease of 10% in residual tumor volume is followed by an increase of 5.5% in median survival in advanced ovarian cancer patients. The diaphragmatic implants can be resected with various surgical techniques, as ABC, peritonectomy or muscle resection. As previously suggested [112], [115]. The complete understanding of the upper abdominal anatomy and of the liver mobilization maneuvers are essential to allow exploration and radical debulking of the diaphragm, and minimizing the risk of major vessels injuries (retro-hepatic caval vein, supra-hepatic veins, diaphragmatic vessels) with severe haemorrhage. It has been reported that the most frequent complication is pleural effusion (42.5%) (114). It was observed, using multivariate analysis, that pleural effusion was statistically well predicted only by hepatic mobilization. Data from 2 reports [107], [113] showed that pulmonary complications represented the main morbidity of diaphragmatic surgery and suggest that the respiratory status of patients with diaphragmatic perforation should be carefully observed postoperatively. The insertion of intra-operative chest tube should be considered in patients undergoing complete liver mobilization and large diaphragmatic peritoneal or full thickness resection. Moreover, a strict early post-operative pulmonary follow-up should reduce the rate of chest complications. In metastatic ovarian carcinoma, involving the dome of the right hepatic lobe are encountered, and this requires radical full-thickness resection of a portion of the muscular diaphragm. Secondary cytoreductive surgery is an acceptable treatment paradigm for patients with platinum sensitive [progression-free survival (PFI) at least 6 to 12 months], recurrent ovarian cancer, who have a good performance status and can subsequently undergo platinum-based salvage chemotherapy [116]. Optimally resected patients have an 18 to 25 months survival advantage over those left with bulky disease ([117], [118] and completely resected patients have overall median survival in excess of 44 months [119], [120]. Hepatic resection of recurrent ovarian and fallopian tube cancers has been reported by Yoon et al [119] with a series of 24 patients collected over 14-years in a single institution. Most (88%) were completely resected and the median survival was 62 months (range, 6 to 94). Fifty percent of patients also required diaphragm resection in this series [121]. Robotic-assisted major and minor hepatic resections have been described for management of benign and malignant liver lesions. It has been reported that conversion to laparotomy was low (5.7%), mean estimated blood loss 262 ml, mortality 0%, and morbidity 21.4% [122]. The majority of the malignant lesions were hepatobiliary primary or metastatic cancers, and only two cases required a partial diaphragm resection.

Port placement for this procedure requires careful preoperative planning based on the anatomic location of the hepatic lesion. The camera should be triangulated 11 cm from the operative table. The laparoscopic Habib 4X® can be useful for cauterization of surrounding parenchyma, especially for lesions deeper in the liver. Diaphragm resection performed by laparotomy results in a pneumothorax that can be evacuated using a red rubber tube and suction from a syringe applied just prior to tying the running suture, while the lung is temporarily hyperinflated. A study [121] reported on management and outcomes from 9 laparoscopic diaphragm injuries or resections accumulated over a 10-year experience. In all cases, a 14 Fr rubber catheter was introduced through a port and placed to water seal while the anesthesiologist hyperinflated the lungs, expelling excess CO₂ from the chest cavity prior to tying the final diaphragm suture. Only one patient had a pneumothorax on post-

extubation chest X-ray and it resolved spontaneously. Based on their experience and, they recommended reserving chest tubes only for patients symptomatic with greater than 30% pneumothorax. In general, performance of hepatic and diaphragm resections for recurrent ovarian cancer can be associated with considerably extended patient survival when followed by platinum-based chemotherapy. This procedure is successfully performed with robotic-assisted laparoscopy. The technique involves, general anesthesia, the patient is placed in a supine position, and 5 trocars are used. Pneumoperitoneum to 12 mmHg is established. A 12-mm trocar for the robotic camera is placed above or below the umbilicus by the Hassen method. Three additional 8-mm trocars are placed at the left upper quadrant (LUQ) epigastric, and right upper quadrant (RUQ) areas under the laparoscopic guidance, respectively. A 12-mm trocar for an assistant was also placed at the LUQ area. Insertion sites of trocars are slightly different for each case because of additional procedures. The 4-arm da Vinci surgical robot system is brought into position and docked following port placement. The operator moved to the console to control the robotic arms. The assistant remained at the patient's left side to change robotic instruments and perform clipping, stapling, intraoperative ultrasonography, and choledochoscope through the 12-mm LUQ trocar site. 30° robotic camera was used. After exploration of the abdominal cavity, intraoperative ultrasonography is used to examine the remaining liver to search for undetectable lesions and obtain adequate surgical resection margins, and hepatic resection is performed.

A closed suction drain catheter is placed in the subhepatic space. The specimen was placed in an endoscopic retrieval bag and removed through a left subcostal mini-laparotomy incision extending from the port site.

Robotic surgery enables the operator to control the robotic system alone and to perform more precise and complex operations, and possibility of remote site surgery (123- 124). Robotic liver surgery provides access to fine structures of the liver and allows visualization of blood vessels and ducts. Three-dimensional vision offers the advantage of improved depth-perception and accuracy. Robotic surgery has several limitations: 1) high cost, 2) inadequate coverage by medical insurance, 3) lack of tactile sense, that can impair surgeons' capacity to make intuitive decisions, 4) lack of training systems, 5) heavy robotic arms and equipments, 6) time-consuming set up, and 7) difficulty in converting to open surgery. (125-126).

In addition, resected hepatic parenchymal metastasis in patients with primary epithelial ovarian carcinoma have favorable outlook with an actuarial 3 year cancer survival of 78% after resection. From surgical standpoint, the use of parenchymal –sparing segmental resections and decrease in the number of hepatic segments resected have substantial influence on decline in blood loss, the use of blood products and, hospital stay (3). Moreover, laparoscopic surgery or robotic assisted laparoscopic surgery is ideal for these cases. The same oncologic rules would apply, including “non –touch technique, RO radical resection and, the achievement of tumor-free surgical margin. Moreover, it was observe that overall morbidity, biliary leakage, transfusion rates, and mortality revealed no difference between the clamp crushing and other alternative transaction techniques (127), (128).

7. Minimally invasive Splenectomy in advanced ovarian cancer

To achieve optimal cytoreductive results in patients with advanced-stage ovarian cancer, splenectomy may be required when disease involves the hilum, capsule, or parenchyma of

the spleen. In patients with extensive omental involvement extending into the splenic hilum, complete removal of the omentum can be safer, with less blood loss, if the spleen is removed en bloc with the omentum.

With the focus on attempting radical cytoreduction to less than 5 mm residual tumor, The frequency with which splenectomy is conducted has increased. The major associated complications of splenectomy include pleural effusions, pneumonia, thrombocytosis with thromboembolism, pancreatic injury, and postoperative sepsis.

The benefit of ultra-radical surgical cytoreduction in the management of ovarian cancer, with the goal of microscopic or minimal residual disease, has been established.

- The minimally invasive robotic surgical technique for splenectomy, involves placing the patient in an incomplete lateral right decubitus position with an anti-Trendelenbourg inclination of about 30°. A patient-side cart with robotic arms is positioned on the left side of the operating table. A 12 mm Hg pneumoperitoneum is created using an open technique and by inserting a Verses needle in the same point and the needle is then replaced with a 15 mm trocar. A 30° laparoscope is used in all cases. Three additional trocars are used. A lateral approach is used. At the start of the procedure the abdominal cavity is examined to detect any accessory spleens, which are identified and removed. The first step consists of the dissection of the inferior splenic pole and ligation of the lower polar vessels, followed by the dissection and ligation of the short gastric vessels. The second step is to approach the splenic pedicle next to the hilum; the ligation of hilar vessels is performed as far as possible from the pancreatic tail.
- This part of the procedure is more precise. The splenorenal ligaments are divided up to the splenodiaphragmatic attachments. The splenic ligament dissection is performed using an ultrasonic device, and the hilar and short gastric vessels are dissected using an endovascular stapler. The surgical specimens are removed, laparoscopically, through an enlarged median supra or subumbilical incision using an endobag, and the drain is removed within 48 hours, to avoid the risk of postoperative infections.

For optimal laparoscopic splenectomy, first, a gentle dissection to avoid incidental hemorrhages or parenchymal rupture due to traction on the spleen and cellular dissemination; second, accurate hemostasis and transection of the hilar vessels, and the identification and removal of accessory spleens that can cause the failure of the surgical procedure. For successful laparoscopic splenectomy, the semi lateral right decubitus position associated with a lateral approach to the splenic hilum reduces the risks of intraoperative bleeding, which is an important reason for conversion to laparotomy. Vaccination in the splenectomized is an important topic. *Streptococcus pneumoniae* is the major pathogen in postsplenectomy sepsis, accounting for 50% to 90% of all infections (129). It has been observed that 31% of patients who had an overwhelming postsplenectomy infection (OPSI) had previously received the appropriate pneumococcal vaccine. OPSIs are rare but well-described, life-threatening events that can occur after splenectomy (131), (132). The incidence of postoperative infection has been estimated to be 3.2%, with a mortality rate of 1.3% (131). When an OPSI occurs, the mortality rate increases to 50% or higher (130). Aggressive early management of postoperative infection is critical to patient survival (129). The interval from the time of a splenectomy to an episode of OPSI varies, from 24 days to 65 years (130). The classic manifestation of OPSI is a brief episode of fever with mild nonspecific symptoms that rapidly evolve into overwhelming septic shock. It is important to initiate empiric broad-spectrum antibiotic therapy against *Serratia pneumoniae*, *Haemophilus influenzae*, and

Neisseria meningitides, and await blood culture results. Preoperatively, patients should receive the pneumococcal vaccine (Pneumovax), *H influenzae* vaccine (if available), and meningococcal vaccinations approximately 10 to 14 days before surgery to maximize immunity (131). Patients who do not receive the vaccine preoperatively should receive the appropriate vaccinations in the immediate postoperative period.

Minor lacerations to the tail of the pancreas that do not involve the major ducts are managed with closed suction drainage. The splenic capsule should not be closed as there is no evidence that will decrease morbidity (132).

8. Minimally invasive colorectal surgery in patients with advanced ovarian cancer

Several studies have compared laparoscopic versus open rectal excision for rectal cancer (133). There were no difference in morbidity, rate of pelvic sepsis and mortality in both groups (134), (135). Histopathologic assessment of the rectal reflects the quality of resection in rectal cancer surgery. Both distal and circumferential resection margins are risk factors of recurrence after rectal excision. (136), (137). It has been shown that laparoscopic approach for rectal cancer is an oncologic safe procedure (138). The surgical technique for rectal metastatic involvement, secondary to advanced ovarian cancer is as follows: patients have a mechanic bowel preparation the day before the operation and prophylactic antibiotics are given at the time of surgery. High ligation of the inferior mesenteric artery and mobilization of the splenic flexure are performed. For upper third rectal tumors, a 5-cm mesorectal excision with end-to-end colorectal anastomosis is performed, for mid and low rectal tumors, TME with pouch supra-anal or anal anastomosis is performed, and abdominoperineal excision is performed when the levator muscle is invaded. Mesorectal excision includes complete removal of the mesorectum circumferentially with preservation of the hypogastric and pelvic plexuses. Extra facial anatomic dissection of the mesorectum is performed. The rectum is transected with a linear stapler, or transanally according to the level of the tumor. For very low tumors, intersphincteric resection is performed to achieve sphincter preservation with clear distal margin. The anastomosis is fashioned using a mechanical circular stapler. A colonic pouch is performed when feasible. A loop ileostomy is performed when the anastomosis is below 5 cm from the anal verge. Pelvic suction drain is inserted. In addition, the distal part of rectal dissection is performed by the perineal approach and a manual coloanal anastomosis is done. The goal of this minimally invasive procedure is to optimize obtaining distal and circumferential safe margins, and to decrease pitfalls due to a difficult laparoscopic low stapling.

Postoperative analgesia is ensured by intravenous morphine chloridrate (patient-controlled administration) at a maximum of 4 mg per hour with a single dose of 1 mg and free interval of 10 minutes for 1 to 2 days. Nasogastric tube is removed at the end of the surgical procedure, fluids intake on postoperative day 1, oral solid food at postoperative day 2 or 3, and bladder catheter removal on postoperative day 3.

The rectal specimen is examined in the operative room to assess distal resection margin, then addressed freshly to the pathologic department pinned on a cork board with moderate tension. The surface of the mesorectum is inked before slicing to assess the circumferential resection margin. Microscopic assessment included tumor infiltration through the bowel wall (pT), presence of positive lymph nodes, and distal and circumferential resection margins. The resection margin is considered as negative if >1 mm (R0) and positive if ≤1 mm (R1).

9. Minimally invasive lower urinary tract surgery in invasive ovarian cancer

In patients with advanced or recurrent ovarian cancer, who have metastatic lower urinary tract involvement, robotic assisted laparoscopic surgery is beneficial. The advantage of using the robotic system is that it enables the surgeon to dissect deeply in the narrow pelvic floor. Also, it offers a better visualization with the binocular optics generating 3-D stereoscopic vision. The utilization of harmonic scalpel allows for control of the pelvic sidewall vessels and transaction of the ligaments attachments around the pelvic structures. The articulating wristed robotic instrument allows for fine sewing. Robotic surgery for advanced ovarian cancer can be achieved by rotating the operating table and relocking the robot at the patient's head. This position will allow dissection and removal of the paraaortic lymph nodes, resection of the upper abdominal metastases, and debulking of diaphragm and live involvement (139). It has been shown that robotic radical prostatectomy; provide a significant advantage in terms of its learning curve especially to surgeons with little or no advanced laparoscopic experience (140). It required only 12 cases to achieve proficiency in performing robotic assisted radical prostatectomy. Total cystectomy with urinary diversion remains the treatment of choice for organ -confined muscle invasive cancer of the urinary bladder. Gil et al. (141) reported laparoscopic radical cystectomy, bilateral lymphadenectomy, and ileal conduit diversion, with the entire procedure carried out by intracorporeal laparoscopic technique. There have been few case reports of laparoscopic anterior pelvic exenteration (142), (143). It has been shown that the procedure is feasible and if combined with intracorporeal urinary diversion. The overall morbidity and hospitalization considerably decreased. It is worth noting that, the goal of extensive surgery; anterior pelvic exenteration should always be resection of the tumor with tumor free margin. Farghaly (144) described the following Technique for urinary bladder invasion in advanced and recurrent ovarian cancer: Once the patient is anesthetized, she is placed in the low lithotomy position in yellowfin stirrups and her arms tucked at her side. After prepping and draping the patient, a standard V-care® Uterine Manipulator (Conmed Endosurgery, Utica, NY) is placed and a foley catheter is inserted into the urinary bladder. A 3-cm incision is made at the umbilicus, a Gelport® is inserted into the incision and trocars are introduced through the port with robotic instruments. The patient is then placed in the steep trendelenberg position and the da Vinci® surgical system (Intuitive Surgical, Sunnyvale, CA) is docked between her legs. A 10-mm robotic 30 degree scope is used through the 10-mm port and robotic monopolar Hook and bipolar Maryland instruments are used through the triangulated robotic ports to perform the procedure. The assistant intermittently places an endoscopic suction device directly through the port. Ovarian cancer tumor and local metastases are debulked to less than 1cm in diameter. The round ligaments are ligated bilaterally, and retroperitoneal spaces are developed. The infundibulopelvic ligaments are skeletonized and transected. A bladder flap is developed, and the uterine arteries and their tributaries are skeletonized and ligated. Pelvic and para-aortic lymph nodes are dissected. The anatomical margins for the lymph node dissection were: medially the ureter, laterally the body of the psoas muscle and genitofemoral nerve, posteriorly, the obturator nerve, inferiorly, the deep circumflex iliac vein, and cephalic of the midportion of the common iliac artery. The superior limit of the para-aortic dissection is the inferior mesenteric artery. The bladder is dissected with its covering. Peritoneum in the cave of Retzius and ureters are clipped and cut. The vagina is cut with harmonic shears and this cut is extended anteriorly

into the urethra and the entire specimen is disconnected. The paracolpos is cut with Ligasure till the levator ani muscle with endopelvic fascia is seen. The entire specimen; uterus, ovarian tumor tissues, fallopian tubes and all lymph nodes removed through the vagina by placing it in endocatch bag, and the vagina is packed to prevent carbon dioxide gas leak. The urinary reservoir is formed by dissecting the terminal ileum about 12 cm from the ileocecal valve and the large colon is dissected 15-20 cm distal to the hepatic flexure. The transection site of the large colon is performed before the middle colonic artery. The distal portion of the ileum is used for continent mechanism of the reservoir. The isolated bowel tract is washed using normal saline solution, ringer lactate and antiseptic povidone-iodine solution. The isolated bowel tract is then filled with 200 ml. of normal saline, and 6 teniamyotomies are performed. The tenia is sectioned across the whole width to the subumbilical layer with, 6 cm between each teniamyotomy. The teniamyotomies are left open in order to increase the reservoir capacity of the pouch. The spatulated ureters are sutured together at the medial side of spatulation to create a trapezoidal plane which is anastomosed to the reservoir as the distal ileum is used as efferent segment of the pouch. The distal ileum is cannulated with 14 Fr catheter. The ileocecal valve is reinforced with 2/0 prolene suture. The tapered ileum is then brought to the anterior abdominal wall.

Pelvic drain is introduced through the 10mm port and ports were removed under vision. The vagina is closed by intracorporeal suturing with 2-0 vicryl and by taking continuous interlocking sutures. The fascia is closed using 0 vicryl suture and the skin is closed with running 4-0 monocryl subcuticular stitch. Estimated operative time 4.6 hours, and average blood loss 210 ml. The pelvic drain is kept for 24-48 hours depending on the drainage. Hospital stay is about 5 days.

This technique offers benefits such as improved surgeon dexterity, enhanced ergonomics and 3-D optics. The utilization of ileal conduit formation for urinary diversion is technically feasible with good result. Also, it is safe, cost effective, with acceptable operative, pathological and short and long term clinical outcome. It retains the advantage of minimally invasive surgery

10. Minimally Invasive Surgery for small bowel involvement in patients with ovarian cancer

Cytoreductive surgery and hyperthermic intraperitoneal chemotherapy have an important role in the management of patients with peritoneal surface and small bowel involvement in patients with advanced stage ovarian cancer. The patterns of intraceolomic dissemination, combined with loco-regional cancer therapies directed at small microscopic residual disease constitute the basis of this therapy. Heat and intraperitoneal chemotherapy given at the time of surgery after a cytoreduction of the peritoneal tumors has resulted in a significant improvement of quality and a prolongation of life in selected patients. The robot-assisted laparoscopic or laparoscopic technique involves greater omentectomy. The greater omentum is mobilized off the transverse colon and its hepatic and splenic flexures are excised using the Harmonic scalpel (Ethicon Inc, Guaynabo, Puerto Rico). The gastrosplenic ligament is transected close to the splenic hilum. Bowel resections are performed with an Endo GIA 3.5/60 mm cartridge (US Surgical, Norwalk, Connecticut). The bowel mesentery is transected with the Harmonic scalpel (Ethicon Inc, Guaynabo, Puerto Rico). At the end of the laparoscopic stage of the procedure, a 5 cm periumbilical midline laparotomy is

performed and the specimens are extracted. Two inflow and 2 outflow perfusion catheters are placed and the skin at the laparotomy and port sites is closed with a running Nylon stitch. Hyperthermic intraperitoneal chemotherapy with cisplatin and adriamycin or mitomycin C for 90 minutes at 43°C is administered using Thermasolutions (Thermasolutions Inc, Pittsburgh, Pennsylvania) perfusion system. At the completion of the heated perfusion, gastrointestinal anastomosis is performed.

11. References

- [1] S.M. Eisenkop and N.M. Spirtos, What are the current surgical objectives, strategies, and technical capabilities of gynecologic oncologists treating advanced epithelial ovarian cancer. *Gynecol. Oncol.* 82 (2001), pp. 489–497.
- [2] O. Zivanovic, E.L. Eisenhauer, Q. Zhou, A. Iasonos, P. Sabbatini and Y. Sonoda et al., The impact of bulky upper abdominal disease cephalad to the greater omentum on surgical outcome for stage IIIC epithelial ovarian, fallopian tube, and primary peritoneal cancer, *Gynecol. Oncol.* 108 (2008), pp. 287–292.
- [3] Jemal A, Siegel R, Ward E, et al. Cancer statistics, 2006. *CA Cancer J Clin* 2006; 56:106–30.
- [4] Young RC, Decker DG, Wharton JT, et al. Staging laparotomy in early ovarian cancer. *JAMA* 1983; 250:3072–6.
- [5] Stier EA, Barakat RR, Curtin JP, et al. Laparotomy to complete staging of presumed early ovarian cancer. *Obstet Gynecol* 1996; 87:737–40.
- [6] Staging announcement. FIGO cancer committee. *Gynecol Oncol* 1986; 50:383–5.
- [7] R.E. Bristow, R.S. Tomacruz, D.K. Armstrong, E.L. Trimble and F.J. Monts, Survival benefit of maximal cytoreductive surgery for advanced ovarian carcinoma during the platinum era: a meta-analysis, *J. Clin. Oncol.* 20 (2002), pp. 1248–1259.
- [8] G.D. Aletti, S.C. Dowdy, B.S. Gostout, M.B. Jones, C.R. Stanhope and T.O. Wilson et al., Aggressive surgical effort and improved survival in advanced-stage ovarian cancer, *Obstet. Gynecol.* 107 (2006), pp. 77–85.
- [9] S.M. Eisenkop and N.M. Spirtos, Procedures required to accomplish complete cytoreduction of ovarian cancer: is there a correlation with “biological aggressiveness” and survival, *Gynecol. Oncol.* 82 (2001), pp. 435–441
- [10] F. Fanfani, G. Ferrandina, G. Corrado, A. Fagotti, H.V. Zakut and S. Mancuso et al., Impact of interval debulking surgery on clinical outcome in primary unresectable FIGO stage IIIc ovarian cancer patients, *Oncology* 65 (2003), pp. 316–322.
- [11] R. Salani, A. Santillan, M.L. Zahurak, R.L. Giuntoli II, G.J. Gardner and D.K. Armstrong et al., Secondary cytoreductive surgery for localized, recurrent epithelial ovarian cancer: analysis of prognostic factors and survival outcome, *Cancer* 109 (2007), pp. 685–691.
- [12] G.D. Aletti, S.C. Dowdy, K.C. Podratz and W.A. Cliby, Surgical treatment of diaphragm disease correlates with improved survival in optimally debulked advanced stage ovarian cancer, *Gynecol. Oncol.* 100 (2006), pp. 283–287.
- [13] M.A. Merideth, W.A. Cliby, G.L. Keeney, T.G. Lesnick, D.M. Nagorney and K.C. Podratz, Hepatic resection for metachronous metastases from ovarian carcinoma, *Gynecol. Oncol.* 89 (2003), pp. 16–21
- [14] S.M. Eisenkop, N.M. Spirtos and W.C. Lin, Splenectomy in the context of primary cytoreductive operations for advanced epithelial ovarian cancer, *Gynecol. Oncol.* 100 (2006), pp. 344–348

- [15] P.M. Magtibay, P.B. Adams, M.B. Silverman, S.S. Cha and K.C. Podratz, Splenectomy as part of cytoreductive surgery in ovarian cancer, *Gynecol. Oncol.* 102 (2006), pp. 369-374
- [16] M.M. Juretzka, N.R. Abu-Rustum, Y. Sonoda, R.J. Downey, R.M. Flores and B.J. Park et al., The impact of video-assisted thoracic surgery (VATS) in patients with suspected advanced ovarian malignancies and pleural effusion, *Gynecol. Oncol.* 104 (2007), pp. 670-674.
- [17] F.J. Montz, J.B. Schlaerth and J.S. Berek, Resection of diaphragmatic peritoneum and muscle: role in cytoreductive surgery for ovarian cancer, *Gynecol. Oncol.* 35 (1989), pp. 338-340
- [18] S.J. Kapnick, C.T. Griffiths and N.J. Finkler, Occult pleural involvement in stage III ovarian carcinoma: role of diaphragmatic resection, *Gynecol. Oncol.* 39 (1990), pp. 135-138
- [19] W. Cliby, S. Dowdy, S.S. Feitoza, B.S. Gostout and K.C. Podratz, Diaphragm resection for ovarian cancer: technique and short-term complications, *Gynecol. Oncol.* 94 (2004), pp. 655-660
- [20] Ghezzi F, Cromi A, Uccella S, et al. Laparoscopy versus laparotomy for the surgical management of apparent early stage ovarian cancer. *Gynecol Oncol.* 2007; 105(2):409-413.
- [21] Chi DS, Abu-Rustum NR, Sonoda Y, et al. The safety and efficacy of laparoscopic surgical staging of apparent stage I ovarian and fallopian tube cancers. *Am J Obstet Gynecol.* 2005;192(5):1614-1619.
- [22] Park JY, Kim DY, Suh DS, et al. Comparison of laparoscopy and laparotomy in surgical staging of early-stage ovarian and fallopian tube cancer. *Ann Surg Oncol.* 2008;15(7):2012-2019.
- [23] Nezhath FR, Ezzati M, Chuang L, et al. Laparoscopic management of early ovarian and fallopian tube cancers: surgical and survival outcome. *Am J Obstet Gynecol.* 2009;200(1):83.e1-6.
- [24] Tozzi R, Köhler C, Ferrara A, et al. Laparoscopic treatment of early ovarian cancer: surgical and survival outcomes. *Gynecol Oncol.* 2004;93(1): 199-203.
- [25] Angioli R, Palaia I, Zullo MA, et al. Diagnostic open laparoscopy in the management of advanced ovarian cancer. *Gynecol Oncol.* 2006;100(3): 455-461.
- [26] Childers JM, Lang J, Surwit EA, et al. Laparoscopic surgical staging of ovarian cancer. *Gynecol Oncol.* 1995;59(1):25-33.
- [27] Ramirez PT, Wolf JK, Levenback C. Laparoscopic port-site metastases: etiology and prevention. *Gynecol Oncol.* 2003;91(1):179-189.
- [28] Havrilesky LJ, Peterson BL, Dryden DK, et al. Predictors of clinical outcomes in the laparoscopic management of adnexal masses. *Obstet Gynecol.* 2003; 102(2):243-251.
- [29] Canis M, Botchorishvili R, Manhes H, et al. Management of adnexal masses: role and risk of laparoscopy. *Semin Surg Oncol.* 2000; 19(1):28-35.
- [30] Bakkum-Gamez JN, Richardson DL, Seamon LG, et al. Influence of intraoperative capsule rupture on outcomes in stage I epithelial ovarian cancer. *Obstet Gynecol.* 2009;113(1):11-17.
- [31] Vergote I, De Brabanter J, Fyles A, et al. Prognostic importance of degree of differentiation and cyst rupture in stage I invasive epithelial ovarian carcinoma. *Lancet.* 2001;357(9251):176-182.

- [32] Abu-Rustum N; Gemigani M, Moore K et al. Total laparoscopic radical hysterectomy with lymphadenectomy using the argon-beam coagulator: pilot data and comparison to laparotomy. *Gynecol Oncol* 2003; 91; P. 402-9
- [33] Magrina J, Mutone N, Weaver A et al. Laparoscopic lymphadenectomy and vaginal or laparoscopic hysterectomy with bilateral salpingo-oophorectomy for endometrial cancer: morbidity and survival. *Am J Obstet Gynecol* 1999; 181; P. 376-81
- [34] Kim YT, Kim SW, Hyung WJ et al. Robotic radical hysterectomy with Pelvic lymphadenectomy for cervical carcinoma: a pilot study. *Gynecol Oncol* 2008; 108 (2):312-16
- [35] Sert B, and Abeler V. Robotic radical hysterectomy in early -stage cervical carcinoma patients, comparing results with total laparoscopic radical hysterectomy cases; the future is now. *Int J Med Robot* 2007; 3; P.224-28
- [36] Fanning J, Fenton B, Purohit M. Robotic radical hysterectomy . *Am J Obstet Gynec* ;2008; 198; P.1-4
- [37] R. Angioli, I. Palaia, M.A. Zullo, L. Muzii, N. Mancini and M. Calcagno et al., Diagnostic open laparoscopy in the management of advanced ovarian cancer, *Gynecol. Oncol.* 100 (2006), pp. 455-461.
- [38] X. Deffieux, D. Castaigne and C. Pomel, Role of laparoscopy to evaluate candidates for complete cytoreduction in advanced stages of epithelial ovarian cancer, *Int. J. Gynecol. Cancer* 16 (suppl. 1) (2006), pp. 35-40.
- [39] A. Fagotti, F. Fanfani, M. Ludovisi, R. Lo Voi, G. Bifulco and A.C. Testa et al., Role of laparoscopy to assess the chance of optimal cytoreductive surgery in advanced ovarian cancer patients: a pilot study, *Gynecol. Oncol.* 96 (2005), pp. 729-735.
- [40] Vazzielli and V. Carone et al., Prospective validation of a laparoscopic predictive model for optimal cytoreduction in advanced ovarian carcinoma, *Am. J. Obstet. Gynecol.* 199 (6) (2008), pp. 642.e1-642.e6.
- [41] A. Fagotti, F. Fanfani, C. Rossitto, D. Lorusso, A.M. De Gaetano and A. Giordano et al., A treatment selection protocol for recurrent ovarian cancer patients: the role of FDG-PET/CT and staging laparoscopy, *Oncology* 75 (3-4) (2008), pp. 152-158.
- [42] A. Fagotti, G. Ferrandina, F. 42. Fanfani, A. Ercoli, D. Lorusso and M. Rossi et al., A laparoscopy-based score to predict surgical outcome in patients with advanced ovarian carcinoma: a pilot study, *Ann. Surg. Oncol.* 13 (2006), pp. 1156-1161.
- [43] Brun, R. Rouzier, S. Uzan and E. Darai, External validation of a laparoscopic-based score to evaluate respectability of advanced ovarian cancers: clues for a simplified score, *Gynecol. Oncol.* 110 (2008), pp. 354-359.
- [44] Ozols RF, Rubin SC, Thomas G, Robboy S: Epithelial Ovarian Cancer. In Hoskins WJ, Perez CA, Young RC (eds): *Principles and Practice of Gynecologic Oncology*, 2nd ed. Philadelphia, Lippincott-Raven, 1997, pp 919-986
- [45] Cain JM, Saigo PE, Pierce VK, Clark DG, Jones WB, Smith DH, Hakes TB, Ochoa M, Lewis JL Jr: A review of second-look laparotomy for ovarian cancer. *Gynecol Oncol* 23:14 -25, 1986
- [46] Ozols RF, Bundy BN, Fowler J, et al.: Randomized phase III study of cisplatin (CIS)/paclitaxel (PAC) versus carboplatin (CARBO/PAC) in optimal stage III epithelial ovarian cancer (OC): a Gynecologic Oncology Group trial (GOG 158). *Proc Am Soc Clin Oncol* 18:356a, 1999 (Abstract 1373)

- [47] Rubin SC, Hoskins WJ, Hakes TB, Markman M, Cain JM, Lewis JL Jr: Recurrence after negative second-look laparotomy for ovarian cancer: analysis of risk factors. *Am J Obstet Gynecol* 159:1094–1098, 1988
- [48] Rubin SC, Hoskins WJ, Saigo PE, Chapman D, Hakes TB, Markman M, Reichman B, Almadrone L, Lewis JL Jr: Prognostic factors for recurrence following negative second-look laparotomy in ovarian cancer patients
- [49] Rubin SC, Randall TC, Armstrong KA, Chi DS, Hoskins WJ: Ten year follow-up of ovarian cancer patients after second-look laparotomy with negative findings. *Obstet Gynecol* 93:21–24, 1999
- [50] Nicoletto MO, Tumolo S, Talamini R, Salvagno L, Franceschi S, Visona E, Marin G, Angelini F, Brigato G, Scarabelli C, Carbone A, Cecchetto A, Prosperi A, Rosabian A, Giusto M, Cima GP, Morassut S, Nascimben O, Vinante O, Fiorentino MV: Surgical second look in ovarian cancer: a randomized study in patients with laparoscopic complete remission—a Northeastern Oncology Cooperative Group–Ovarian Cancer Cooperative Group Study. *J Clin Oncol* 15(3):994–999, 1997
- [51] Quinn MA, Bishop GJ, Campbell JJ, Rodgerson J, Pepperell RJ: Laparoscopic follow-up of patients with ovarian cancer. *Br J Obstet Gynaecol* 87:1132–1139, 1980
- [52] Ozols RF, Fisher RI, Anderson T, Makuch R, Young RC: Peritoneoscopy in the management of ovarian cancer. *Am J Obstet Gynecol* 140:611–619, 1981
- [53] Berek JS, Griffiths CT, Leventhal JM: Laparoscopy for second-look evaluation in ovarian cancer. *Obstet Gynecol* 58:192–198, 1981
- [54] Gadducci A, Sartori E, Maggino T, Zola P, Landoni F, Fanucchi A, Palai N, Alessi C, Ferrero AM, Cosio S, Cristofani R: Analysis of failures after negative second look in patients with advanced ovarian cancer: an Italian multicenter study. *Gynecol Oncol* 68:150–155, 1998
- [55] Casey AC, Farias-Eisner R, Pisani AL, Cirisano FD, Kim YB, Muderspach L, Futoran R, Leuchter RS, Lagasse LD, Karlan BY: What is the role of reassessment laparoscopy of gynecologic cancers in 1995? *Gynecol Oncol* 60:454–461, 1996
- [56] Abu-Rustum NR, Barakat RR, Siegel PL, Venkatraman E, Curtin JP, Hoskins WJ: Second-look operation for epithelial ovarian cancer: Laparoscopy or laparotomy? *Obstet Gynecol* 88:549–553, 1996
- [57] Copeland LJ, Gershenson DM, Wharton JT, Atkinson EN, Sneige N, Edwards CL, Rutledge FN: Microscopic disease at second-look laparotomy in advanced ovarian cancer. *Cancer* 55:472–478, 1985
- [58] Hoskins WJ, Rubin SC, Dulaney E, Chapman D, Almadrone L, Saigo P, Markman M, Hakes T, Reichman B, Jones WB, et al.: Influence of cytoreductive surgery at the time of second-look laparotomy on the survival of patients with epithelial ovarian cancer. *Gynecol Oncol* 34:365–371, 1989
- [59] Lippman SM, Alberts DS, Slymen DJ, Weiner S, Aristizabal SA, Luditch A, Davis JR, Surwit EA: Second-look laparotomy in epithelial ovarian carcinoma. Prognostic factors associated with survival duration. *Cancer* 61(12):2571–2577, 1988.
- [60] Williams L, Brunetto VL, Yordan E, DiSaia PJ, Creasman WT: Secondary cytoreductive surgery at second-look laparotomy in advanced ovarian cancer: a Gynecologic Oncology Group Study. *Gynecol Oncol* 66(2):171–178, 1997
- [61] Barakat RR, Almadrone L, Venkatraman ES, Aghajanian C, Brown C, Shapiro F, Curtin JP, Spriggs D: A phase II trial of intraperitoneal cisplatin and etoposide as

- consolidation therapy in patients with Stage II–IV epithelial ovarian cancer following negative surgical assessment. *Gynecol Oncol* 69:17–22, 1988
- [62] Markman M, Reichman B, Hakes T, Lewis JL Jr, Jones W, Rubin S, Barakat R, Curtin J, Almadrone L, Hoskins W: Impact on survival of surgically defined favorable responses to salvage intraperitoneal chemotherapy in small-volume residual ovarian cancer. *J Clin Oncol* 10:1479–1484, 1992
- [63] Barter J, Barnes WA: Second Look Laparotomy, in Rubin SC, Sutton SP (eds.): *Ovarian Cancer*, New York, McGraw–Hill, 1993
- [64] Abu-Rustum NR, Barakat RR, Siegel PL, Venkatraman E, Curtin JP, Hoskins WJ. Second-look operation for epithelial ovarian cancer: laparoscopy or laparotomy? *Obstet Gynecol.* 1996;884:549–53.
- [65] Husain A, Chi DS, Prasad M, Abu-Rustum N, Barakat RR, Brown CL, et al. The role of laparoscopy in second-look evaluations for ovarian cancer. *Gynecol Oncol.* 2001;80:44–7.
- [66] Clough K, Ladonne JM, Nos C, Renolleau C, Validire P, Durand JC. Second look for ovarian cancer: laparoscopy or laparotomy? A prospective comparative study. *Gynecol Oncol.* 1999;72:411–17.
- [67] Berek JS, Griffith CT, Leventhal JM. Laparoscopy for second-look evaluation in ovarian cancer. *Obstet Gynecol.* 1981; 58:192–8.
- [68] Lele S, Piver MS. Interval laparoscopy prior to second-look laparotomy in ovarian cancer. *Obstet Gynecol.* 1986;68: 345–9.
- [69] Fanning J, Fenton B, Purohit M. Robotic radical hysterectomy. *Am J Obstet Gynecol.* 2008;198:649–650.
- [70] Russo A, Cirelli G, Cassese E, Delli Ponti D, Sgambata R, Cecere F, et al. Second-look in ovarian cancer: laparoscopy or laparotomy? *Minerva Ginecol.* 2001;53: 146–54.
- [71] Husain A, Chi DS, Prasad M, Abu-Rustum N, Barakat RR, Brown CL, et al. The role of laparoscopy in second-look evaluations for ovarian cancer. *Gynecol Oncol.* 2001;80: 44–7.
- [72] Fanning J, Fenton B, Switzer M, Johnson J, Clemons J. Laparoscopically assisted vaginal hysterectomy for uteri weighing 1,000g or more. *JLS.* 2008;12:376–379. [
- [73] Fanning J, Trinh H. Feasibility of laparoscopic ovarian debulking at recurrence in patients with prior laparotomy debulking. *Am J Obstet Gynecol.* 2004;190:1394–1397. [PubMed]
- [74] Johnson N, Barlow D, Lethaby A, Tavender E, Curr E, Garry R. Surgical approach to hysterectomy for benign gynaecological disease. *Cochrane Database Syst Rev.* 2005;1:DC003677.
- [75] Curtin, R. Malik, E.S. Venkatraman, R.R. Barakat and W.J. Hoskins, Stage IV ovarian cancer: impact of surgical debulking, *Gynecol. Oncol.* 64 (1) (1997), pp. 9–12.
- [76] g, Z.Y. Zhang and S.M. Cai et al., Cytoreductive surgery for stage IV epithelial ovarian cancer, *J. Exp. Clin. Cancer Res.* 18 (4) (1999), pp. 449–454.
- [77] P.C. Liu, I. Benjamin and M.A. Morgan et al., Effect of surgical debulking on survival in stage IV ovarian cancer, *Gynecol. Oncol.* 64 (1) (1997), pp. 4–8.
- [78] R.E. Bristow, F.J. Montz, L.D. Lagasse, R.S. Leuchter and B.Y. Karlan, Survival impact of surgical cytoreduction in stage IV epithelial ovarian cancer, *Gynecol. Oncol.* 72 (3) (1999), pp. 278–287

- [79] R. Eitan, D.A Levine and N. Abu-Rustum et al., The clinical significance of malignant pleural effusions in patients with optimally debulked ovarian carcinoma, *Cancer* 103 (7) (2005), pp. 1397-1401
- [80] D.S. Chi, C.C. Franklin and D.A. Levine et al., Improved optimal cytoreduction rates for stages IIIC and IV epithelial ovarian, fallopian tube, and primary peritoneal cancer: a change in surgical approach, *Gynecol. Oncol.* 94 (3) (2004), pp. 650-654.
- [81] S.M. Eisenkop, R.L. Friedman and H.J. Wang, Complete cytoreductive surgery is feasible and maximizes survival in patients with advanced epithelial ovarian cancer: a prospective study, *Gynecol. Oncol.* 69 (2) (1998), pp. 103-108.
- [82] G.D. Aletti, S.C. Dowdy, K.C. Podratz and W.A. Cliby, Surgical treatment of diaphragm disease correlates with improved survival in optimally debulked advanced stage ovarian cancer, *Gynecol. Oncol.* 100 (2) (2006), pp. 283-287.
- [83] D.F. Silver, Full-thickness diaphragmatic resection with simple and secure closure to accomplish complete cytoreductive surgery for patients with ovarian cancer, *Gynecol. Oncol.* 95 (2) (2004), pp. 384-387
- [84] Chi DS, Abu-Rustum NR, Sonoda Yet al. The benefit of video-assisted thoracoscopic surgery before planned abdominal exploration in patients with suspected advanced ovarian cancer and moderate to large pleural effusions. *Gynecol Oncol.* 2004;94:307-311
- [85] S.M. Eisenkop, Thoracoscopy for the management of advanced epithelial ovarian cancer—a preliminary report, *Gynecol. Oncol.* 84 (2) (2002), pp. 315-320
- [86] Kapnick SJ, Griffiths CT, Finkler NJ. Occult pleural involvement in stage III ovarian carcinoma: role of diaphragm resection. *Gynecol Oncol.* 1990;39:135-138.
- [87] Eitan R, Levine DA, Abu-Rustum Net al. The clinical significance of malignant pleural effusions in patients with optimally debulked ovarian carcinoma. *Cancer.* 2005;103:1397-1401.
- [88] Bristow RE, Tomacruz RS, Armstrong DK et al. Survival effect of maximal cytoreductive surgery for advanced ovarian carcinoma during the platinum era: a meta-analysis. *J Clin Oncol.* 2002;20:1248-1259.
- [89] Munkarah AR, Hallum AV 3rd, Morris Met al. Prognostic significance of residual disease in patients with stage IV epithelial ovarian cancer. *Gynecol Oncol.* 1997;64:13-17.
- [90] Blanchard P, Plantade A, Pagés C, Afchain P, Louvet C, Tournigand C, de Gramont A. Isolated lymph node relapse of epithelial ovarian carcinoma: Outcomes and prognostic factors. *Gynecol Oncol.* 2007;104:41-5.
- [91] Lim MC, Lee HS, Jung DC, Choi JY, Seo SS, Park SY. Pathological diagnosis and cytoreduction of cardiophrenic lymph node and pleural metastasis in ovarian cancer patients using video-assisted thoracic surgery. *Ann Surg Oncol.* 2009;16:1990-6.
- [92] Uzan C, Morice P, Rey A, Pautier P, Camatte S, Lhommè C, Haie-Meder C, Duvillard P, Castaigne D. Outcomes after combined therapy including surgical resection in patients with epithelial ovarian cancer recurrence(s) exclusively in lymph nodes. *Ann Surg Oncol.* 2004;11(7):658-64
- [93] O. Zivanovic, E.L. Eisenhauer, Q. Zhou, A. Iasonos, P. Sabbatini and Y. Sonoda et al., The impact of bulky upper abdominal disease cephalad to the greater omentum on

- surgical outcome for stage IIIc epithelial ovarian, fallopian tube, and primary peritoneal cancer, *Gynecol. Oncol.* 108 (2008), pp. 287–292
- [94] R.E. Bristow, R.S. Tomacruz, D.K. Armstrong, E.L. Trimble and F.J. Monts, Survival effect of maximal cytoreductive surgery for advanced ovarian carcinoma during the platinum era: a meta-analysis, *J. Clin. Oncol.* 20 (2002), pp. 1248–1259
- [95] G.D. Aletti, S.C. Dowdy, B.S. Gostout, M.B. Jones, C.R. Stanhope and T.O. Wilson et al., Aggressive surgical effort and improved survival in advanced-stage ovarian cancer, *Obstet. Gynecol.* 107 (2006), pp. 77–85.
- [96] S.M. Eisenkop and N.M. Spirtos, Procedures required to accomplish complete cytoreduction of ovarian cancer: is there a correlation with “biological aggressiveness” and survival, *Gynecol. Oncol.* 82 (2001), pp. 435–441
- [97] F. Fanfani, G. Ferrandina, G. Corrado, A. Fagotti, H.V. Zakut and S. Mancuso et al., Impact of interval debulking surgery on clinical outcome in primary unresectable FIGO stage IIIc ovarian cancer patients, *Oncology* 65 (2003), pp. 316–322.
- [98] R. Salani, A. Santillan, M.L. Zahurak, R.L. Giuntoli II, G.J. Gardner and D.K. Armstrong et al., Secondary cytoreductive surgery for localized, recurrent epithelial ovarian cancer: analysis of prognostic factors and survival outcome, *Cancer* 109 (2007), pp. 685–691
- [99] S.M. Eisenkop and N.M. Spirtos, What are the current surgical objectives, strategies, and technical capabilities of gynecologic oncologists treating advanced epithelial ovarian cancer?, *Gynecol. Oncol.* 82 (2001), pp. 489–497.
- [100] G.D. Aletti, S.C. Dowdy, K.C. Podratz and W.A. Cliby, Surgical treatment of diaphragm disease correlates with improved survival in optimally debulked advanced stage ovarian cancer, *Gynecol. Oncol.* 100 (2006), pp. 283–287.
- [101] M.A. Merideth, W.A. Cliby, G.L. Keeney, T.G. Lesnick, D.M. Nagorney and K.C. Podratz, Hepatic resection for metachronous metastases from ovarian carcinoma, *Gynecol. Oncol.* 89 (2003), pp. 16–21
- [105] S.M. Eisenkop, N.M. Spirtos and W.C. Lin, Splenectomy in the context of primary cytoreductive operations for advanced epithelial ovarian cancer, *Gynecol. Oncol.* 100 (2006), pp. 344–348.
- [103] P.M. Magtibay, P.B. Adams, M.B. Silverman, S.S. Cha and K.C. Podratz, Splenectomy as part of cytoreductive surgery in ovarian cancer, *Gynecol. Oncol.* 102 (2006), pp. 369–374
- [104] M.M. Juretzka, N.R. Abu-Rustum, Y. Sonoda, R.J. Downey, R.M. Flores and B.J. Park et al., The impact of video-assisted thoracic surgery (VATS) in patients with suspected advanced ovarian malignancies and pleural effusion, *Gynecol. Oncol.* 104 (2007), pp. 670–674
- [105] F.J. Montz, J.B. Schlaerth and J.S. Berek, Resection of diaphragmatic peritoneum and muscle: role in cytoreductive surgery for ovarian cancer, *Gynecol. Oncol.* 35 (1989), pp. 338–340
- [106] S.J. Kapnick, C.T. Griffiths and N.J. Finkler, Occult pleural involvement in stage III ovarian carcinoma: role of diaphragmatic resection, *Gynecol. Oncol.* 39 (1990), pp. 135–138.
- [107] S. Dowdy, S.S. Feitoza, B.S. Gostout and K.C. Podratz, Diaphragm resection for ovarian cancer: technique and short-term complications, *Gynecol. Oncol.* 94 (2004), pp. 655–660.


- [108] E.L. Eisenhauer, M.I. D'Angelica, N.R. Abu-Rustum, Y. Sonoda, W.R. Jarnagin and R.R. Barakat et al., Incidence and management of pleural effusion after diaphragm peritonectomy or resection for advanced Mullerian cancer, *Gynecol. Oncol.* 103 (2006), pp. 871–877.
- [109] G.D. Aletti, S.C. Dowdy, K.C. Podratz and W.A. Cliby, Surgical treatment of diaphragm disease correlates with improved survival in optimally debulked advanced stage ovarian cancer, *Gynecol. Oncol.* 100 (2006), pp. 283–287.
- [110] K. Devolder, F. Amant, P. Neven, T. van Gorp, K. Leunen and I. Vergote, Role of diaphragmatic surgery in 69 patients with ovarian cancer, *Int. J. Gynecol. Cancer.* 18 (2008), pp. 363–368.
- [111] P.E. Colombo, A. Mourregot, M. Fabbro, M. Gutowski, B. Saint-Aubert and F. Quenet et al., Aggressive surgical strategies in advanced ovarian cancer: a monocentric study of 203 stage IIIc and IV patients, *Eur. J. Surg. Oncol.* 35 (2009), pp. 135–143.
- [112] G. Deppe, V.K. Malviya, G. Boike and A. Hampton, Surgical approach to diaphragmatic metastases from ovarian cancer, *Gynecol. Oncol.* 24 (1986), pp. 258–260
- [113] S.M. Kehoe, E.L. Eisenhauer and D.S. Chi, Upper abdominal surgical procedures: liver mobilization and diaphragm peritonectomy/resection, splenectomy, and distal pancreatectomy, *Gynecol. Oncol.* 111 (2008), pp. S51–S55.
- [114] S.C. Dowdy, R.T. Loewen, G. Aletti, S.S. Feitoza and W. Cliby, Assessment of outcomes and morbidity following diaphragmatic peritonectomy for women with ovarian carcinoma, *Gynecol. Oncol.* 109 (2008), pp. 303–307
- [115] E. Chereau, M. Ballester, F. Selle, A. Cortez, C. Pomel and E. Darai et al., Pulmonary morbidity of diaphragmatic surgery for stage III/IV ovarian cancer, *BJOG* 116 (2009), pp. 1062–1068.
- [116] Janicke F, Holscher M, Kuhn W, von Hugo R, Pache L, Siewert JR, Graeff H. Radical surgical procedure improves survival time in patients with recurrent ovarian cancer. *Cancer* 1992;70:2129–36.
- [117] Gadducci A, Iaconi P, Cosio S, Fanucci A, Cristofani R, Genazzani AR. Complete salvage surgical cytoreduction improves further survival of patients with late recurrent ovarian cancer. *Gynecol Oncol* 2000;79:344–9.
- [118] Eisenkop SM, Friedman RL, Spirtos NM. The role of secondary cytoreductive surgery in the treatment of patients with recurrent epithelial ovarian carcinoma. *Cancer* 2000;88:144–53.
- [119] Yoon SS, Jarnagin WR, Fong Y, DeMatteo RP, Barakat RR, Blumgart LH, Chi DS. Resection of recurrent ovarian or fallopian tube carcinoma involving the liver. *Gynecol Oncol* 2003;91:383–8.
- [120] Giulianotti PC, Coratti A, Sbrana F, Addeo P, Bianco FM, Busch NC, Annechiarico M, Benedetti E. Robotic liver surgery: Results for 70 resections. *Surgery* 2011;149: 29–39.
- [121] Idrees K, Bartlett DL. Robotic liver Surgery. *Surg Clin N Am* 2010;90:761–74.
- [122] Aron M, Colombo Jr JR, Turna B, Stein RJ, Haber G-P, Gill IS. Diaphragmatic repair and/or reconstruction during upper abdominal urologic laparoscopy. *J Urol* 2007;178:2444–50.
- [123] Vidovszky TJ, Smith W, Ghosh J, Ali MR. Robotic cholecystectomy: learning curve, advantages, and limitations. *J Surg Res.* 2006;136:172–178.

- [124] Hashizume M, Tsugawa K. Robotic surgery and cancer: the present state, problems and future vision. *Jpn J Clin Oncol.* 2004;34:227-237
- [125] D'Annibale A, Morpurgo E, Fisco V, Trevisan P, Sovernigo G, Orsini C, et al. Robotic and laparoscopic surgery for treatment of colorectal disease. *Dis Colon Rectum.* 2004;47:2162-2168.
- [126] Nguyen MM, Das S. The evolution of robotic urologic surgery. *Urol Clin North Am.* 2004;31:653-658. vii
- [127] Jarngin WR, Gonenm, Fong Y et al. Improvement in perioperative outcome after hepatic resection: Analysis of 1803 consecutive cases over the past decade. *Ann Surg* 2002, 236 (4), P. 397-407
- [128] Rahbari NN, Koch M, Schmidt T et al. Meta-analysis of the clamp-crushing technique for transection of the parenchyma in elective hepatic resection: back to where we started. *Ann Surg Oncol* 2009, 16 (3), 630-9
- [129] Farghaly SA. Observation on the surgical aspect of resection of Noncolorectal Vonneuroendocrine Hepatic Parenchymal Metastasis in Patients with Primary Epithelial Ovarian Carcinoma. *Gynecol Oncol* 2009,;115 (2): 319
- [130] G.D. Aletti, S.C. Dowdy, B.S. Gostout, M.B. Jones, C.R. Stanhope and T.O. Wilson et al., Aggressive surgical effort and improved survival in advanced-stage ovarian cancer, *Obstet Gynecol* 107 (2006), pp. 77-85.
- [131] A.M. Lynch and R. Kapila, Overwhelming postsplenectomy infection, *Infect Dis Clin North Am* 10 (1996), pp. 693-707141..
- [132] Gelmini R, Romano F, Quaranta N, Caprotti R, Tazzioli G, Colombo G, Saviano M, Uggeri F. Suturless and stapless laparoscopic splenectomy using radiofrequency: Ligasure device. *Surg Endosc* 2006;20:991-994.-986.
- [133] W. Krivit, Overwhelming postsplenectomy infection, *Am J Hematol* 2 (1977), pp. 193-201.
- [134] E.C. Ellison and P.J. Fabri, Complications of splenectomy. Etiology, prevention, and management, *Surg Clin North Am* 63 (1983), pp. 1313-1330.
- [135] Birbeck KF, Macklin CP, Tiffin NJ, et al. Rates of circumferential resection margin involvement vary between surgeons and predict outcomes in rectal cancer surgery. *Ann Surg.* 2002;235:449-457
- [136] Nagtegaal ID, Quirke P. What is the role for the circumferential margin in the modern treatment of rectal cancer? *J Clin Oncol.* 2008;26:303-312
- [137] Braga M, Frasson M, Vignali A, et al. Laparoscopic resection in rectal cancer patients: outcome and cost-benefit analysis. *Dis Colon Rectum.* 2007;50:464-471.
- [138] Bandera CA and Magrina F. Robotic surgery in Gynecologic Oncology. *Obstet Gynecol* 2009;1: 25-30
- [139] Ahlering TE, Skarecky D, Lee D, Llayman RV. Successful transfer of open surgical skills to a laparoscopic environment using a robotic interface: initial experience with laparoscopic radical prostatectomy. *J Urol* 2003; 5: 1738-1741
- [140] Gill I, Fergany A, Klein E et al. Laparoscopic radical cystectomy with ileal conduit performed completely intracorporeally; the initial 2 cases. *Urology* 2000; 56:26-29
- [141] Lin MY, Fan EW, Chiuaw et al. Laparoscopy -assisted transvaginal total exenteration for locally advanced cervical cancer with bladder invasion after radiotherapy. *J Endourol* 2004; 9: 867-870

- [142] Pomel C, Rouzier M, Pocard A et al. Laproscopic total pelvic exenteration for cervical cancer . *Gynecol Oncol.* 2003;91(3):616-8
- [143] Farghaly SA. Robotic-assisted laparoscopic anterior pelvic exenteration in patients with advanced ovarian cancer: Farghaly's Technique. *Eur J Gynecol Oncol* 2010; 31(4): 361-3
- [144] Verwaal VJ, Bruin S, Boot H, et al. 8-year follow-up of randomized trial: cytoreduction and hyperthermic intraperitoneal chemotherapy versus systemic chemotherapy in patients with peritoneal carcinomatosis of colorectal cancer *Ann Surg Oncol.* 2008;15(9):2426–2432

INTECH

INTECH



Ovarian Cancer - Clinical and Therapeutic Perspectives

Edited by Dr. Samir Farghaly

ISBN 978-953-307-810-6

Hard cover, 338 pages

Publisher InTech

Published online 15, February, 2012

Published in print edition February, 2012

Worldwide, Ovarian carcinoma continues to be responsible for more deaths than all other gynecologic malignancies combined. International leaders in the field address the critical biologic and basic science issues relevant to the disease. The book details the molecular biological aspects of ovarian cancer. It provides molecular biology techniques of understanding this cancer. The techniques are designed to determine tumor genetics, expression, and protein function, and to elucidate the genetic mechanisms by which gene and immunotherapies may be perfected. It provides an analysis of current research into aspects of malignant transformation, growth control, and metastasis. A comprehensive spectrum of topics is covered providing up to date information on scientific discoveries and management considerations.

How to reference

In order to correctly reference this scholarly work, feel free to copy and paste the following:

Samir A. Farghaly (2012). Minimally Invasive Surgical Procedures for Patients with Advanced and Recurrent Ovarian Cancer, *Ovarian Cancer - Clinical and Therapeutic Perspectives*, Dr. Samir Farghaly (Ed.), ISBN: 978-953-307-810-6, InTech, Available from: <http://www.intechopen.com/books/ovarian-cancer-clinical-and-therapeutic-perspectives/minimally-invasive-surgical-techniques-for-advanced-and-recurrent-ovarian-cancer>

INTECH
open science | open minds

InTech Europe

University Campus STeP Ri
Slavka Krautzeka 83/A
51000 Rijeka, Croatia
Phone: +385 (51) 770 447
Fax: +385 (51) 686 166
www.intechopen.com

InTech China

Unit 405, Office Block, Hotel Equatorial Shanghai
No.65, Yan An Road (West), Shanghai, 200040, China
中国上海市延安西路65号上海国际贵都大饭店办公楼405单元
Phone: +86-21-62489820
Fax: +86-21-62489821