

25

Benign Disease of the Breast

Eva J. Kantelhardt

INTRODUCTION

A variety of conditions may occur in the breast. Starting from congenital abnormalities, conditions due to hormonal changes throughout reproductive life and physiological differences due to pregnancy and lactation are known. There may also be infections and proliferative diseases. Women with breast problems will present at all ages.

The most important issue is to bear in mind that a patient complaining of breast symptoms can have breast cancer as well as a benign condition. When breast cancer is not treated early, median survival will be around 3 years. With early diagnosis and treatment, the woman has a good chance of being cured.

This chapter deals with benign breast disease; Chapter 30 describes breast cancer diagnosis and treatment in detail (see Table 1 for differential diagnosis). It is important to understand that breast cancer can mimic even benign disease, especially benign solid tumors.

Both benign and malignant breast disorders can present with: a palpable mass; skin dimpling, thickening, or erythema; pain; nipple discharge and inversion or distortion; or an abnormal screening mammogram with no clinical findings¹. Available methods in low-resource settings for investigating breast problems include mainly clinical breast examination and ultrasound.

Please keep in mind that clinical examination and imaging can only give additional information on whether a breast disease is malignant or not. The definite diagnosis is made through histology. Due to accessibility and anatomy of the breast, invasive procedures such as fine-needle aspiration, core biopsy and excisional biopsy can be done easily to obtain cytology or preferably histology. It

Table 1 Differential diagnosis of benign breast lesions

<i>Benign condition</i>	<i>Key findings</i>
Fibroadenoma	Firm tumor in the breast, well-defined, mobile ('breast mouse')
Fibrocystic changes	Consolidated area, rather diffuse
Cyst	On ultrasound black, round area with defined margins
Mastitis	Signs of infection
Papilloma	Unilateral bloody nipple discharge
Hormonal imbalance	Bilateral clear or milky nipple discharge
Mastodynia	Recurrent breast pain associated with menstrual cycle

is very important to collect as much information as possible prior to the definite surgical treatment as the approach to surgery in malignant and benign disease differs. With inadequate surgery you may worsen the chances of your patient being cured. You can find more information on breast cancer surgery in Chapter 30.

Several benign breast diseases have been shown to increase the risk of developing breast cancer in later life. This depends on the nature of the lesion – proliferative disease (e.g. sclerosing adenosis, ductal hyperplasia, radial scar, intraductal papilloma) increases the risk of breast cancer, even more when accompanied by atypia (atypical hyperplasia) (see paragraph on fibrocystic changes in this chapter). But the specific attributes of the patient also influence the risk of developing breast cancer (age, family history, ethnicity, time since benign lesion, hormonal status)². Differences are described, for

example in African-American compared to American women³. Women who present with a benign breast lesion should be informed that they should have regular breast examinations in the future.

SIGNS AND SYMPTOMS

History

You can find additional information on history taking in breast diseases in Chapter 1. When taking a specific history on breast problems, the following aspects should be considered. Ask about:

- Any change in shape, outline or texture of the breast
- Any palpable tumor
- Any new retraction of the nipple
- Any new swelling or peau d'orange (orange-peel skin)
- Any change in size (note most women have breasts of unequal in size)
- Any new secretion from the nipple (bloody? serous?) (note that small and bilateral amounts of serous nipple discharge are normal, especially in women who have breastfed)
- Any localized (unilateral?) pain, burning, pins and needles
- Any breast pain, feeling of pressure, hyperthermia, any redness of the skin
- Increase or decrease in size
- Last menstrual period, regular cycle? length of cycle?
- Any previous breast disease, operation or incision
- Any personal history of malignancies (especially ovarian, endometrial or colorectal cancer)
- Any personal history of gynecological operations (oophorectomy) or radiation of the lower abdomen
- Any family history of breast disease especially breast cancer, focus on mother and sisters
- Number of pregnancies, parity, duration of breastfeeding, age at first pregnancy
- Use of oral or injectable contraceptives, could the patient be pregnant?
- Age at menarche, age at menopause (if applicable)
- History on last self-breast examination
- Last gynecological and breast examination by health personnel
- Previous imaging done (ultrasound, mammography). Don't forget to ask if the patient has signs of chronic disease (tuberculosis, cancer)

- Weight loss of 10% within the last 6 months
- Night sweating
- Cough, contact with tuberculosis-positive people
- Ascites, lymphedema on the arm
- Weakness. To have some additional information which can help you to rule out cancer and tuberculosis.

Clinical breast examination

For details on breast examination, inspection and palpation of the axilla and breast see Chapter 1. Keep in mind that in premenopausal women it is best to do clinical breast examination (CBE) immediately after the menstrual period as it is most easy to assess at this point. On examination you may note changes of the skin or nipple. Peau d'orange is an appearance like the peel of an orange due to swelling and fluid retention (Figure 1).

The breast of a postmenopausal patient is much easier to assess than that of a premenopausal patient due to involution (transformation of firm breast tissue into softer fatty tissue after menopause). On palpation you may find lesions with a diameter of 1 cm and above. In cases of large breasts only 2 cm lesions may be palpated. In the elderly even smaller lesions may be found (Table 2).

An instructional article on clinical breast examination may be found at: <http://www.npjjournal.org/article/S1555-4155%2807%2900653-8/abstract> and the website of International Agency for Research on Cancer (IARC) gives good instructions: <http://screening.iarc.fr/breastselfexamination.php>.

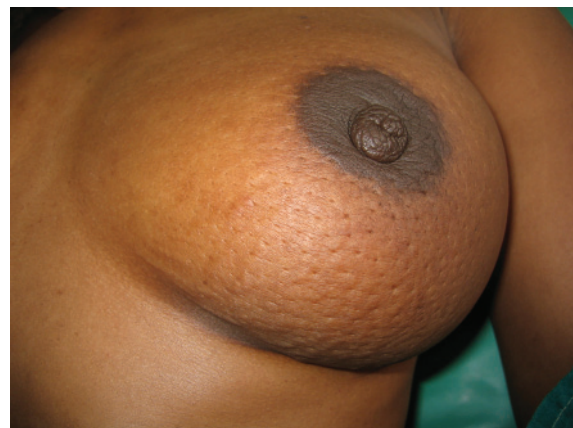

Figure 1 Peau d'orange. Courtesy of Erik Erichsen, Ethiopia

GYNECOLOGY FOR LESS-RESOURCED LOCATIONS

Table 2 Key findings on clinical examination of the breast

<i>Benign condition</i>	<i>Key findings on clinical examination</i>
Fibroadenoma	Solitary, firm tumor in the breast, well-defined, round or oval, mobile ('breast mouse'), may be multiple, usually grow slowly, usually known for months or years, lymph nodes not palpable
Fibrocystic changes	Consolidated area, may be painful on examination (due to cyclic changes), patient may point to the area, margins rather diffuse, lymph nodes not palpable
Cyst	Impingement on palpation, they may be multiple, lymph nodes not palpable
Mastitis	Redness, local warming, pain, fever, development of abscess, lymph nodes may be swollen and painful
Papilloma	Unilateral (sometimes bilateral if papilloma in both breasts) bloody nipple discharge, lymph nodes not palpable
Hormonal imbalance	Bilateral clear or milky nipple discharge, lymph nodes not palpable
Mastodynia	Recurrent breast pain, associated with menstrual cycle, lymph nodes not palpable

Table 3 Key findings on ultrasound of the breast

<i>Benign condition</i>	<i>Key findings on ultrasound</i>
Fibroadenoma	A solid, homogeneous, echo-dense, round or oval mass, may be multiple, clearly distinguished from surrounding breast tissue
Fibrocystic changes	Consolidated area, may have multiple small cystic (black) areas, not easy to distinguish from the surrounding breast tissue
Cyst	Easy to find, black, round area with a clear margin, sometimes multiple, the diameter is easily assessed
Mastitis	An abscess may be seen as darker area with clear margins, fluid inside with movements of floating particles (pus)
Papilloma	In rare cases fluid may surround the papilloma making it visible as a small mass on a pedicle, usually closer to the nipple area
Hormonal imbalance	No specific sonographic findings
Mastodynia	No specific sonographic findings

NECESSARY DIAGNOSTICS

Note that all imaging only gives additional information on the breast disease – the final diagnosis is made by histology.

Ultrasound

The most important and widely available method of imaging is ultrasound (see Chapter 1 on how to do breast ultrasound). The main information gained even by beginners is to distinguish a cystic lesion with fluid inside from a solid lesion (Table 3; Figure 2).

Mammography

The use of mammography is to gain information on suspicious lesions or to monitor a patient with a positive family history (mother or sister or male

family member affected by breast cancer). But note: patients with palpable lesions need cytological or histological confirmation even without mammography (see Chapter 30)! Mammography is not recommended as a standard investigation in low-resource settings which is partly due to its unavailability in such areas.

Magnetic resonance imaging in high-resource settings

The use of magnetic resonance imaging (MRI) is limited to centers with a specialization of the radiologist.

Cytology and microbiology

Assessment of cells from the lesion under the microscope may give valuable hints to the diagnosis.

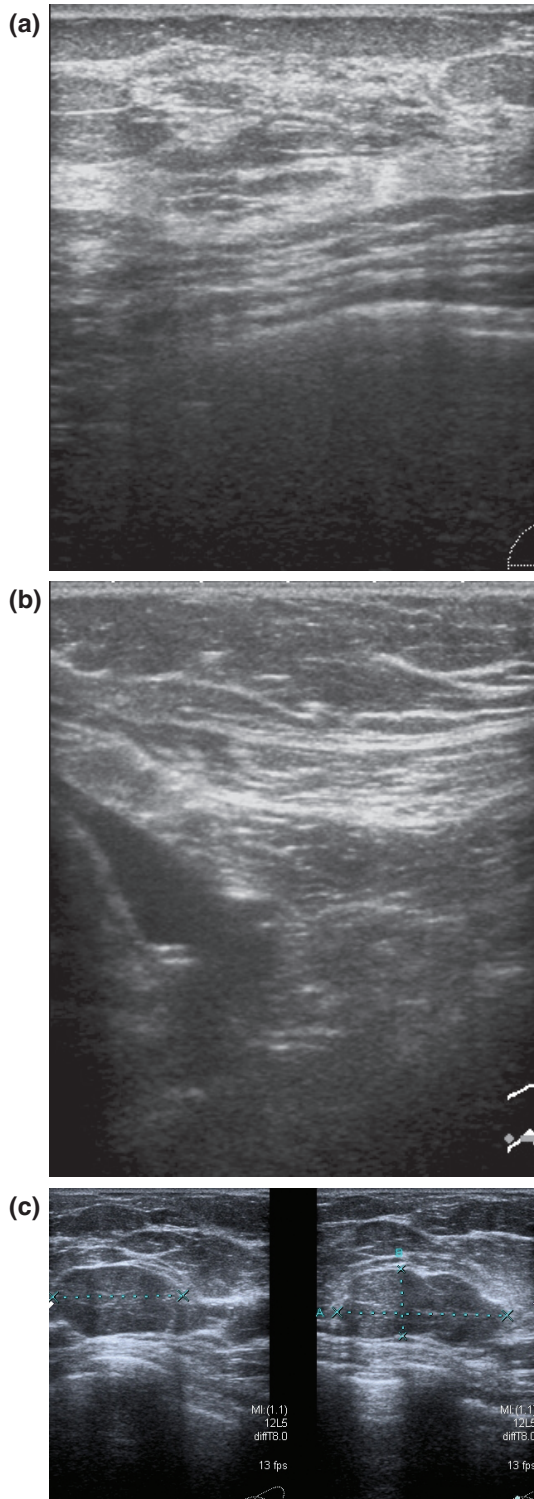


Figure 2 Examples of ultrasound findings of the breast: (a) normal breast tissue; (b) normal axillary finding; (c) palpable mass – fibroadenoma suspected. Courtesy of Regina Grosse, Germany

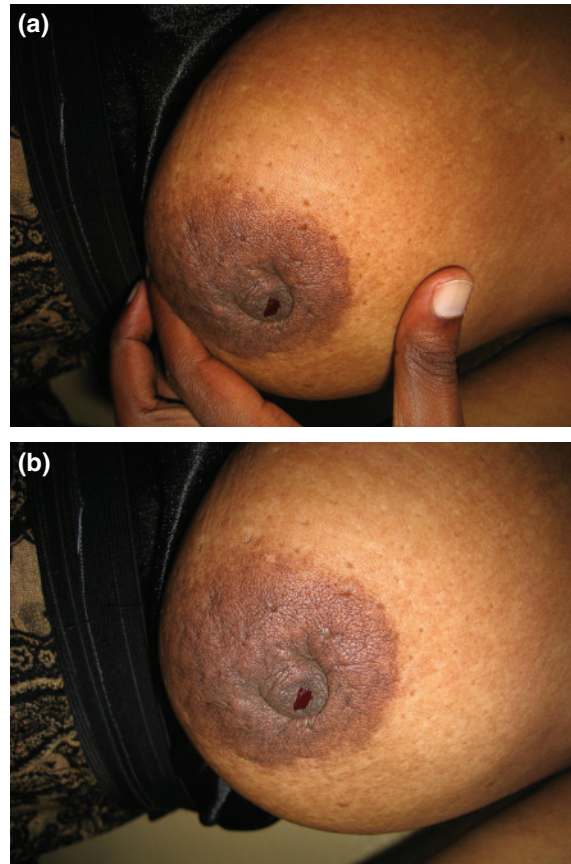


Figure 3 Bloody secretion from the nipple – the woman can express the fluid (be ready to make a cytologic examination!). Courtesy of Erik Erichsen, Ethiopia

Cytology is done with relatively little equipment (see Chapter 30 on how to do a fine-needle biopsy). Material may be gained from secretion of the nipple, a fine-needle aspiration of the lesion or with a wet swab from an incisional biopsy (Figure 3). Bacteria or transformed cells may be identified and give hints to the final diagnosis.

Pictures may be taken with a digital camera or a cell phone through the microscope and then sent by e-mail to a pathology center (telepathology).

Minimal invasive breast biopsy or core biopsy

A minimal invasive breast biopsy (MIBB) is usually done to have a histological diagnosis before definite surgical treatment. The method of taking core-needle biopsies needs costly equipment. If available, it is convenient to obtain histology under local anesthesia and, depending on the result, properly plan the surgical removal of the lesion. See Chapter 30 for details.

Excisional biopsy for diagnostic purpose

To come to a clear diagnosis with non-invasive methods and without histology is nearly impossible in many cases. If ever possible, try to obtain histology and review cases to assure the quality of the clinical diagnosis. As the breast is easily accessible, excisional biopsies should be done rather generously in the risk group. Local anesthesia with lignocaine is used for superficial lesions; general anesthesia is needed for deeper localization. Excise the lesion (from a semi-circular incision above the

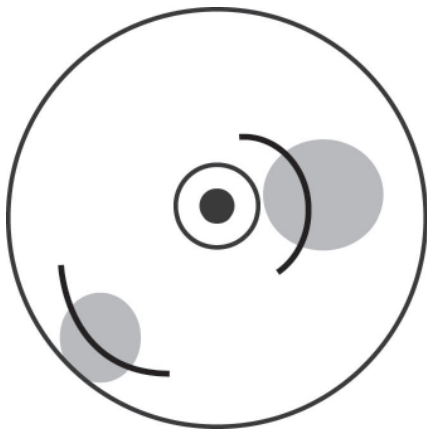

Figure 4 Semicircular incisions directly above the lesions should be used in the breast if breast cancer is suspected

lesion, far or close around the areola) *in toto* – adding a margin of >1 cm if breast cancer is still to be ruled out (Figure 4). Then you will have the diagnosis and at the same time you have treated the patient by removing the mass!

Sometimes removing the total mass is not possible – taking only a small specimen is called incisional biopsy.

Laboratory investigations

In any cases of fever or obvious infection monitor the full blood count. Prolactin may be helpful to rule out a prolactinoma in galactorrhea of female or male patients. This is a costly investigation for high-resource settings. In low-resource settings the patient must be referred to a specialized center. You might as well give bromocriptine as a therapeutic trial (see below).

DIFFERENTIAL DIAGNOSIS AND TREATMENT

See flow chart in Figure 5.

Mastitis puerperalis

Refer to a textbook of obstetrics for mastitis occurring during breastfeeding and keep in mind that even breastfeeding women can develop breast

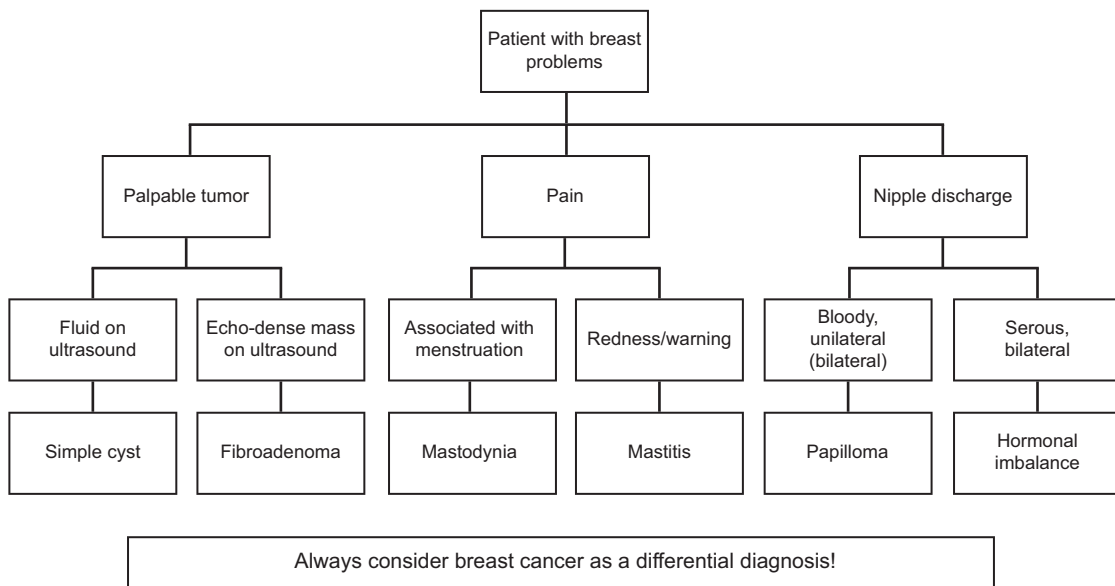


Figure 5 Flow chart of leading signs/symptoms – differential diagnosis

cancer! Any mastitis or abscess that doesn't resolve under antibiotic or surgical treatment should raise your suspicion of malignancy.

Mastitis non-puerperalis

This is a condition often associated with hyperprolactinemia. Therefore treatment with antibiotics should be accompanied by bromocriptine 5 mg o.d. for 2–3 months. Side-effects (hypotension and headache) are less if the tablet is administered vaginally. A course of antibiotics and anti-inflammatory medication should be given. In cases of a newly forming abscess, red light may help. In cases of abscess formation, an incision with removal of necrotic tissue and drainage may be necessary (Figure 6). At that point you can take tissue for histology/cytology as well. Beware not to remove the whole breast tissue! A drain (glove-drain = 3 × 10 cm piece of sterile glove) may be put in (consider two communicating incisions – one for the drain below, one for irrigation from above). Regular irrigation with normal saline (e.g. daily) must be done.

Keep in mind that breast cancer can present itself as inflammatory carcinoma which looks exactly like mastitis. So if your treatment doesn't work after some time, consider breast cancer as the diagnosis.

In case a chronic fistula has developed, surgical treatment must include the complete excision of the fistula. This should be done by an experienced surgeon.

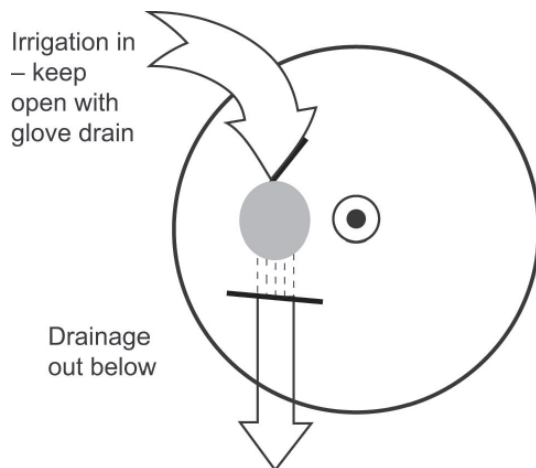


Figure 6 Irrigation of breast abscess (grey) – top incision to infuse irrigation by syringe, the fluid will rinse out from the lower incision. Keep both incisions open with a glove drain

Persisting nipple discharge/galactorrhea (in female and male)

Certain medication/drugs may induce hyperprolactinemia leading to galactorrhea! Ask about phenothiazine, tricyclic antidepressants, haloperidol (Haldol®), methyl dopa, metoclopramide, cimetidine, domperidone and heroine. In case there is no drug-related reason for the suspected hormonal imbalance, you may suspect hyperprolactinemia.

Ask about oligomenorrhea, fertility problems and visual problems (reduced field of vision). Assess by asking the patient to follow your finger sideways and say when she doesn't see it anymore. If the patient has visual problems she may have a macroprolactinoma (located in the pituitary gland occupying space at the sella region of the brain, this leads to bilateral compression of the optical nerves) and needs referral for special investigations. Often a microprolactinoma causes symptoms of hyperprolactinemia. A microprolactinoma does not occupy space in the sella region of the brain; no impairment of the vision is expected. If she has only oligomenorrhea and problems in conceiving, give bromocriptine 2.5 mg o.d. as described in Chapter 16 on subfertility.

Other infections

These are rather rare. Tuberculosis is seldom seen in the breast, but can be found more frequently in the immune-compromised, e.g. advanced HIV disease. Usually it has secondarily developed from primary pulmonary tuberculosis. Appearance is typically with a painless swelling, increasing in size and eventually pus will be expelled, but atypical signs are seen as well such as mastitis or multiple fistulae (Figure 7). Treatment is according to local guidelines on tuberculosis. Surgical treatment is rarely needed.

A patient with syphilis may also develop lesions in the breast – especially hard ulcers. Treatment is according to local guidelines (see Chapter 17 on sexually transmitted diseases).

Mastodynia

'Pain in the breast' is present in the last week before menstruation in many women (up to 50%). This may be accompanied with nausea, headache and mood fluctuations – called premenstrual syndrome. Exclude other underlying causes (any tumor, infection and trauma). Explain about the benign nature of the syndrome. Advise use of a firm bra and the

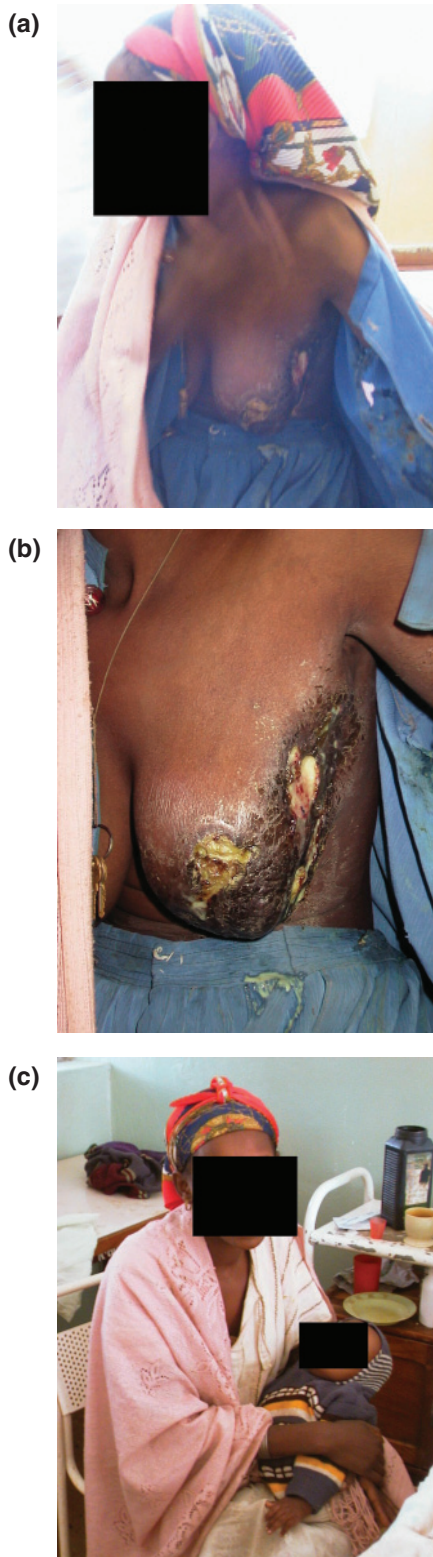

Figure 7 Patient with tuberculosis of the left breast. Courtesy of Erik Erichsen, Ethiopia

use of non-steroidal anti-inflammatory drugs (NSAIDs) in case of severe pain (e.g. diclofenac tablet 50mg t.d.s.). Local application of progesterone (gel) may help where it is available. In cases where contraceptives are used this may reduce symptoms. Contraceptives with higher gestagens, including injectables, may decrease symptoms after an initial (around 3 months) phase of increasing symptoms⁴.

Benign tumors

The most common benign tumors in premenopausal patients (mostly around the age of 20 years) are fibroadenoma. Fibroadenoma usually grow slowly, are firm and mobile on palpation and often multiple in appearance. Growth is accelerated in adolescence, during pregnancy and before menopause. Breast cancer or phyllodes tumor must be considered as a differential diagnosis but there is no risk of developing cancer from a fibroadenoma. In cases of rapid growth, large size (>4 cm) or concern of the patient, surgical removal is indicated. Fibroadenoma may be larger (>5 cm) in the African population. The excision can usually be done under local anesthesia. Extirpation should be *in toto*; histology will confirm the diagnosis.

An operation on a fibroadenoma in a young women is illustrated in Figure 8.

The patient complained of a mobile mass in the right breast. On clinical examination, no axillary lymph nodes were present (Figure 8a, b). On ultrasound, fibroadenoma was strongly suspected with no signs of malignancy. The surgical technique of fibroadenoma extirpation is as follows: position the patient's arm outwards at a 90° angle. If the mass is located at the lower quadrants, a submammary incision may be chosen. Otherwise a semicircular para-alveolar incision gives better cosmetic results. Identify and incise the submammary fold (Figure 8c). As fibroadenoma are usually very mobile, fix the tumor with your fingers or let your assistant do this. Dissect the fatty tissue and breast tissue on top of the fibroadenoma with dissecting scissors until you reach the capsule of the tumor (Figure 8d). Dissect the thin layers of the capsule carefully with dissecting scissors or bluntly by using your index finger to avoid removing too much normal breast tissue (Figure 8e). The fibroadenoma is extirpated manually *in toto*; only the white, firm, nodular tissue is removed (Figure 8f). Usually a

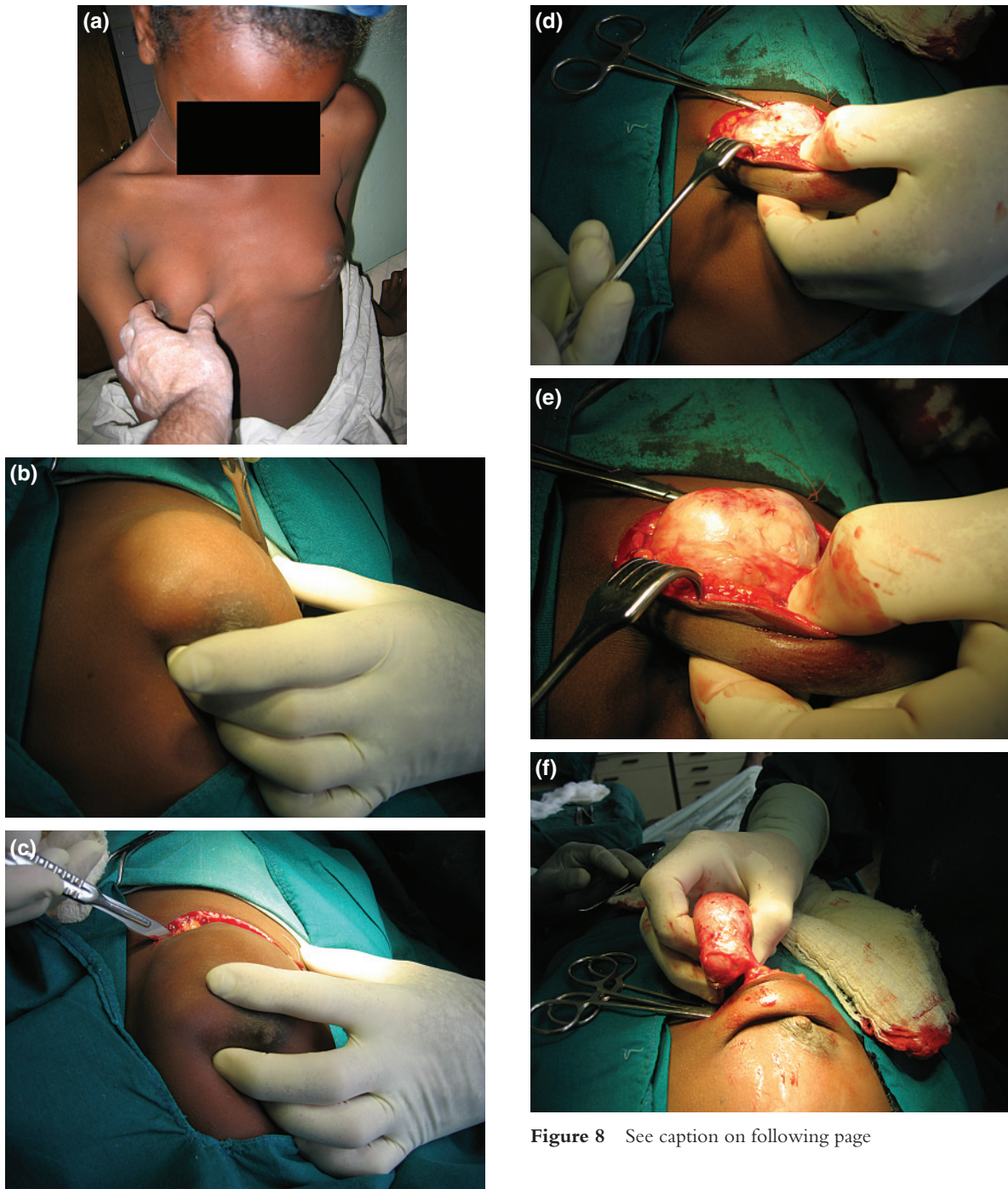


Figure 8 See caption on following page

pedicle is found at one end of the fibroadenoma. Vessels are located here so ligation should be done (Figure 8g). Breast tissue in premenopausal women is well vasculated. Take great care in hemostasis to avoid hematoma. A postoperative bandage around the breast/thorax is advisable. The fibro-

adenoma specimen should be sent to pathology (Figure 8h).

Lipoma may also appear in the breast. Lipoma are soft on palpation, may grow considerably and can lead to asymmetric breast volume. While doing surgery one should carefully identify the margins of

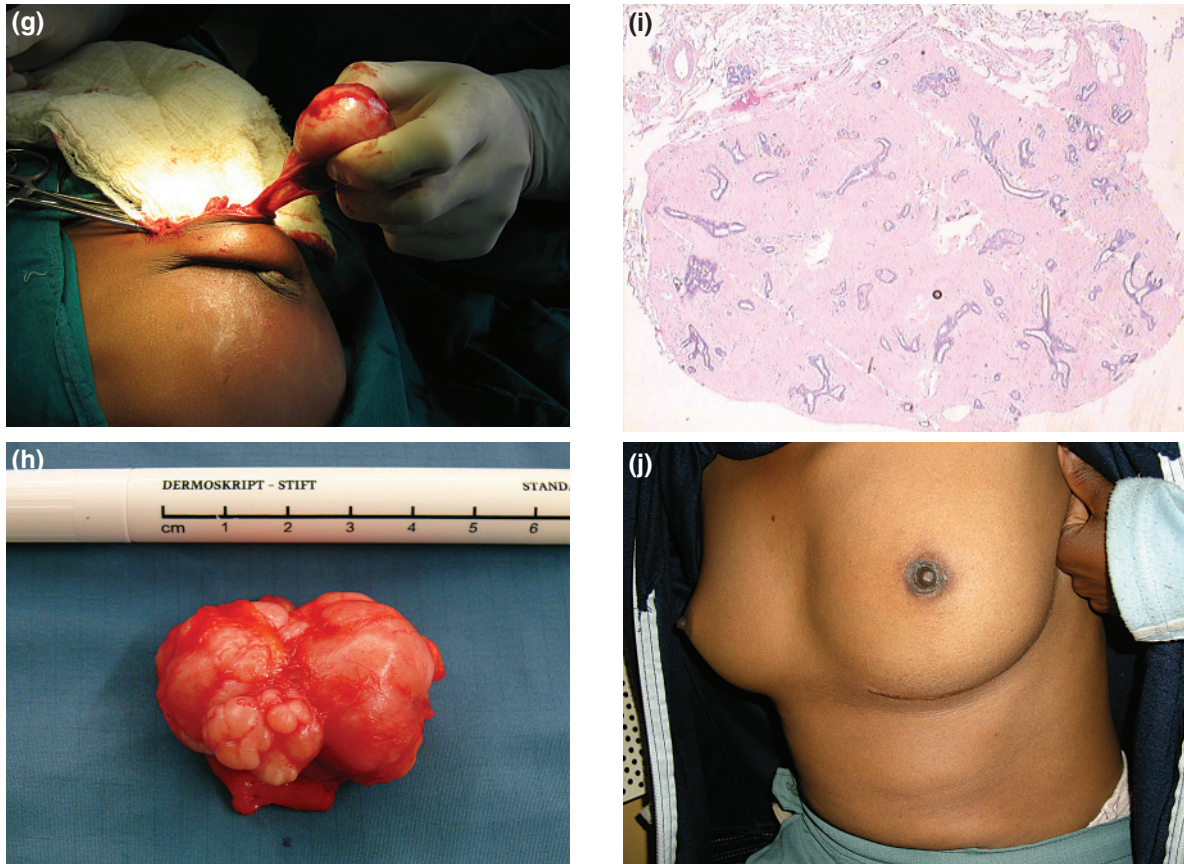


Figure 8 An operation on a fibroadenoma in a young woman. (a, b) Clinical examination. (c–h) The surgical technique of fibroadenoma extirpation (see text). (i) The fibroadenoma specimen for pathology. (j) Example of a submammary scar after excision of fibroadenoma – it is hardly seen! Courtesy of: (a–g, j) Erik Erichsen, Ethiopia; (h) Regina Grosse, Germany; (i) Joerg Buchmann, Germany

the lesion in order to avoid removal of too much or too little tissue since the fat of the breast is similar to the fat of the lipoma.

Fibrocystic changes

This is a remodeling of the breast tissue that takes place in women 20–50 years of age. Due to excessive estrogen levels compared to progesterone fibrotic changes, epithelial proliferation, widening of milkducts and formation of cysts may occur. This may be on multiple sites as well as bilateral. This is the most common benign disease of the breast.

Fibrocystic changes (also called mastopathy) may appear as (macro and micro) cysts and solid lesions, including adenosis, epithelial hyperplasia with or without atypia, apocrine metaplasia, radial scar or papilloma. In cases of histologically confirmed

lesions, the pathologist should identify non-proliferative lesions, proliferative lesions without atypia and proliferative lesions with atypia (Figure 9).

Around 4% of benign palpable lesions will have proliferative disease. Women with proliferative disease, especially with atypia, have a greater risk of developing breast cancer (up to five times higher than the general population, a higher risk for premenopausal women, a higher risk with a first-degree relative with breast cancer; the risk will decline after the discovery of the lesion). Regular follow-up of the patient (especially the young patient or patients with a positive family history) should be done at a specialized breast center with mammography available if possible. Otherwise routine follow-up is recommended (CBE) – there is no detailed evidence on the frequency, 6–12 months seems feasible.

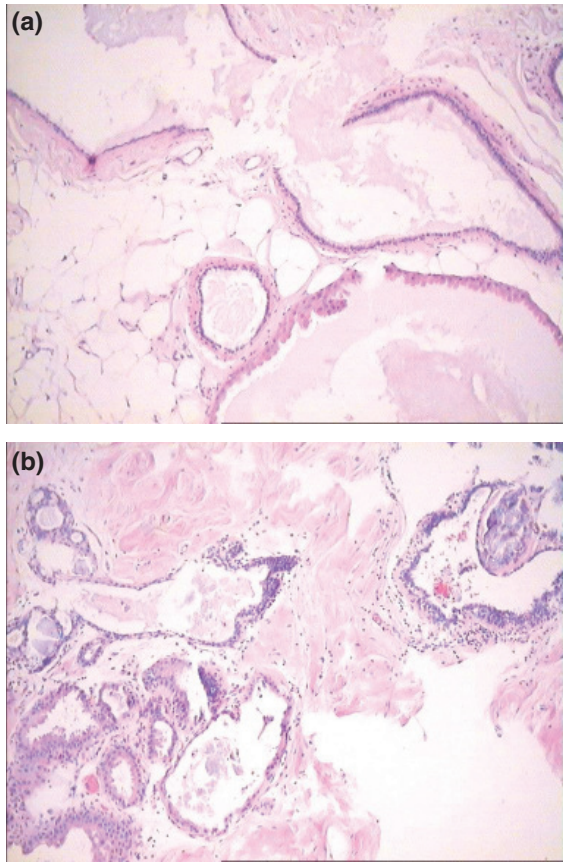


Figure 9 Histologic findings of fibrocystic changes (non-proliferative). Courtesy of Joerg Buchmann, Germany

Cysts may cause pain, alarm the patient or may hide more serious underlying pathology. Usually they are solitary, 30% of patients experience multiple cysts. A cyst with a smooth lining is easily seen on ultrasound. Cysts may be drained with a syringe (use minimum 14G to assure aspiration of the sometimes viscous fluid). In cases of repeated filling, a surgical removal of the lining is needed.

Fibrotic changes may lead to multiple small nodules (adenosis) as well. These can cause pain. Histologic confirmation may be necessary to rule out a malignant lesion (age group is similar to breast cancer) – it is strongly indicated when an intracystic mass is present.

Milk duct papilloma

This is a proliferation of the epithelium of a mammary duct. It may occur isolated or in the presence

of mastopathia. Unilateral, sometimes bilateral (in cases of bilateral papilloma) bloody or serous secretions from the nipple are seen. Be aware that papilloma may have proliferative epithelium and become malignant. Cytology should be done before any intervention (see Chapter 30 on how to do that). This might not always be conclusive.

An excision of the duct should be done in cases of suspicious cytology or persistent bloody secretion. When the patient is under general anesthesia, a few milliliters of methylene-blue are injected into the duct opening in the areola where the secretion is coming from to mark the correct duct. Take care that the dye stays for 20–30 min inside the duct! Usually the papilloma are not far from the nipple. Therefore the skin incision should be performed in a semicircular manner parallel to the areola (e.g. 0.5 cm) in the normal skin (Figure 10). Carefully explore the area behind the nipple to identify the blue milk duct. The structure is fragile directing to one of the breast quadrants. Try to follow the duct until it abruptly stops. The small papilloma (most likely not visible as such) is sitting at the end of the occluded duct. Excise a specimen around the end of the duct of $2 \times 2 \times 2$ cm as well as the duct itself. If you cannot find the duct properly, take a specimen from behind the nipple in the shape of a piece of cake directing to the quadrant drained by the duct. The nipple does not need to be touched – the papilloma is within the tissue *behind* the nipple!

Note: advise the patient NOT to manipulate or express fluid from the nipple as long as possible before the surgery. It is essential to find the correct duct by expressing the fluid immediately before injecting the dye into the duct.

Phyllodes tumor

This is a tumor with benign, borderline and malignant variants. The tumor grows from the stromal cells of the breast; 70% of cases are benign, mostly in young women. The tumor presents as a firm, palpable mass and may grow very fast, even within weeks. Occurrence is mostly before menopause. The differential diagnosis is a fibroadenoma – note that those patients with a phyllodes tumor are on average 15 years older. Wide excision of the lesion with clear negative margins is indicated to avoid recurrence which is more frequent than in fibroadenoma (Figure 11). Axillary dissection is not indicated (even in malignant forms). In cases of

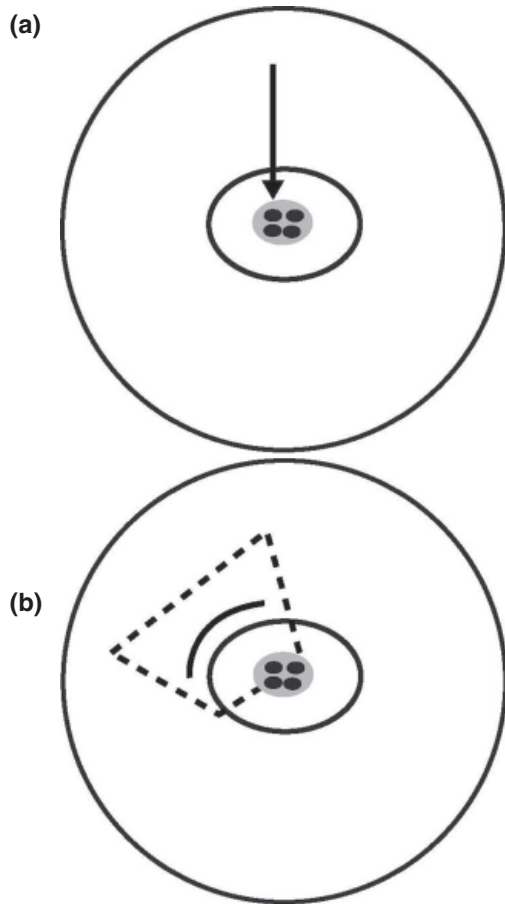


Figure 10 (a) Identification of the secreting duct. (b) Semicircular incision, removing a cake-piece shaped specimen behind the areolar. If possible follow the duct filled with methylene blue. No removal of skin or nipple is needed!

malignancy, mastectomy should be offered to avoid recurrence (see Chapter 30). Due to the huge size of the mass, closure of the wound after the operation may be a problem. Be aware that a skin graft may be necessary.

Mammary Paget's disease

See Chapter 30.

Congenital abnormalities in female and in male

Any part of the breast may be located aberrantly in the embryonic mammary line (axilla down to inguinal region). Additional mammary gland tissue may appear especially in the axilla. Such tissue with-

out drainage to the nipple may swell and become painful during lactation.

An extra nipple or nipple and areola are seen in up to 5% of female patients (often in the axilla, along the breast or the submammary fold). In cases of persistent pain surgical removal may be indicated.

Poland's syndrome (in female or male) is a rare complex malformation due to missing development of the pectoral muscle. Usually areola and nipple are present and the mammary gland is missing. The hand may also be involved with brachydactyly (short fingers). Other abnormalities may be present.

Micromastia

There are several reasons for bilateral hypoplasia of the breasts. Of course the size of breasts may vary considerably between individuals and may just represent a normal variation. Keep in mind that some syndromes cause hypoplastic development of the breasts such as Turner syndrome, adrenogenital syndrome or other forms of intersexuality. Also patients with anorexia nervosa or malnutrition may present with micromastia.

Macromastia

During puberty as well as pregnancy excessive growth of one or both mammary glands may occur. This can lead to psychological problems as well as back pain (weight!), lymphedema of the breast or ulceration due to problems with hygiene. Plastic surgery may be considered. Remember that a patient complaining of breast symptoms may simply be pregnant. So rule out pregnancy in a patient complaining of swollen and painful breasts.

CONCLUSIONS

Benign breast diseases are common. Take all changes of the breast seriously and have in mind it could be breast cancer. Unless it is obviously benign, only histology may rule out breast cancer. When performing surgery beware when operating on the lesion – include larger or smaller margins according to the findings and do not remove the whole breast tissue. Any infection needs close monitoring, care and enough patience for healing – otherwise a large abscess may form easily.

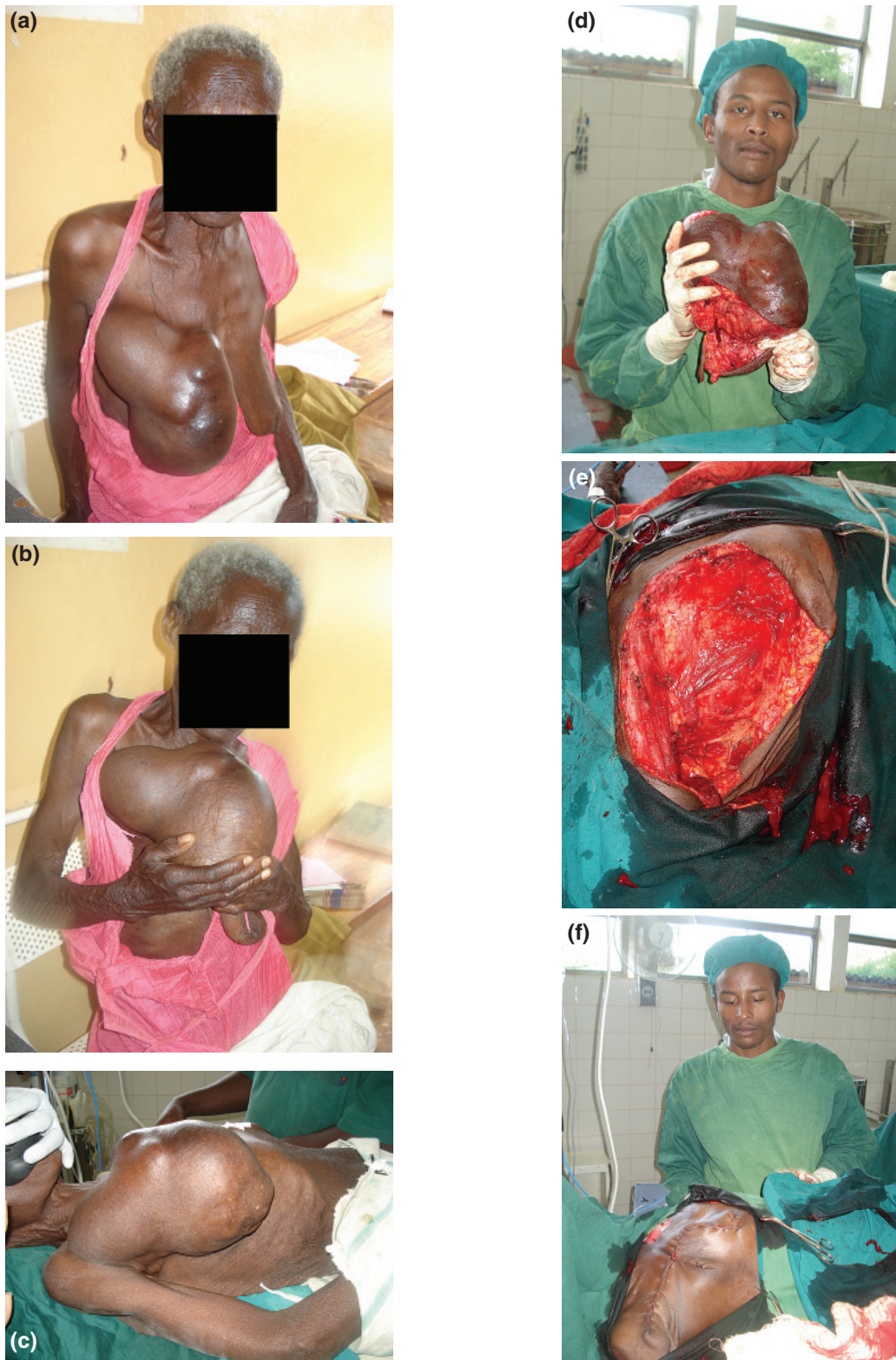

Figure 11 Operation of a giant phyllodes tumor with rotational skin flaps. Courtesy of Erik Erichsen, Ethiopia

GYNECOLOGY FOR LESS-RESOURCED LOCATIONS

Note: the breast is not only essential for breast-feeding but also part of the women's identity!

ACKNOWLEDGEMENT

I am grateful to Erik Erichsen (Ethiopia), Regina Grosse and Joerg Buchmann (Germany) who have contributed significantly to the chapter by providing their excellent photographs. Gabriele Anna Braun (Germany) has kindly commented on the chapter.

REFERENCES

1. Guray M, Sahin AA. Benign breast diseases: classification, diagnosis, and management. *Oncologist* 2006;11:435–49
2. Hartmann LC, Sellers TA, Frost MH, *et al.* Benign breast disease and the risk of breast cancer. *N Engl J Med* 2005;353:229–37
3. Worsham MJ, Raju U, Lu M, *et al.* Risk factors for breast cancer from benign breast disease in a diverse population. *Breast Cancer Res Treat* 2009;118:1–7
4. Schindler AE. Dydrogesterone and other progestins in benign breast disease: an overview. *Arch Gynecol Obstet* 2011;283:369–71