

# Conservative Surgical Management

C. B-Lynch and H. Shah

## INTRODUCTION

A key factor in the surgical management of postpartum hemorrhage is the awareness of predisposing factors<sup>1-3</sup> and the readiness of therapeutic teams consisting of obstetric, anesthetic and hematology staff<sup>3,4</sup>.

In the past, the surgical management of postpartum hemorrhage included use of an intrauterine pack, with or without thromboxane<sup>5</sup>, thrombogenic uterine pack<sup>6</sup>, ligation of uterine arteries<sup>7</sup>, ligation of internal iliac artery<sup>8</sup>, stepwise devascularization<sup>9</sup> and, finally, subtotal or total abdominal hysterectomy<sup>10</sup>. Most of these are discussed in detail in other chapters of this text.

A more conservative procedure, now colloquially known as the Brace suture technique, was first described by B-Lynch and colleagues in 1997<sup>3</sup>. Along with later modifications by Hayman and colleagues<sup>11</sup> and Cho and colleagues<sup>12</sup>, this<sup>13</sup> may prove more effective than radical surgery for the control of life-threatening postpartum hemorrhage<sup>3,11,12</sup>. Although subtotal and total abdominal hysterectomy are still available and indeed useful in their own right, they should be considered as a last resort.

Common causes of postpartum hemorrhage are listed in Table 1, which is not to mean that additional causes cannot or do not exist. Most, if not all, are considered in references to postpartum hemorrhage in modern standard textbooks of obstetrics and further described in the other chapters of this volume. Three important points merit attention.

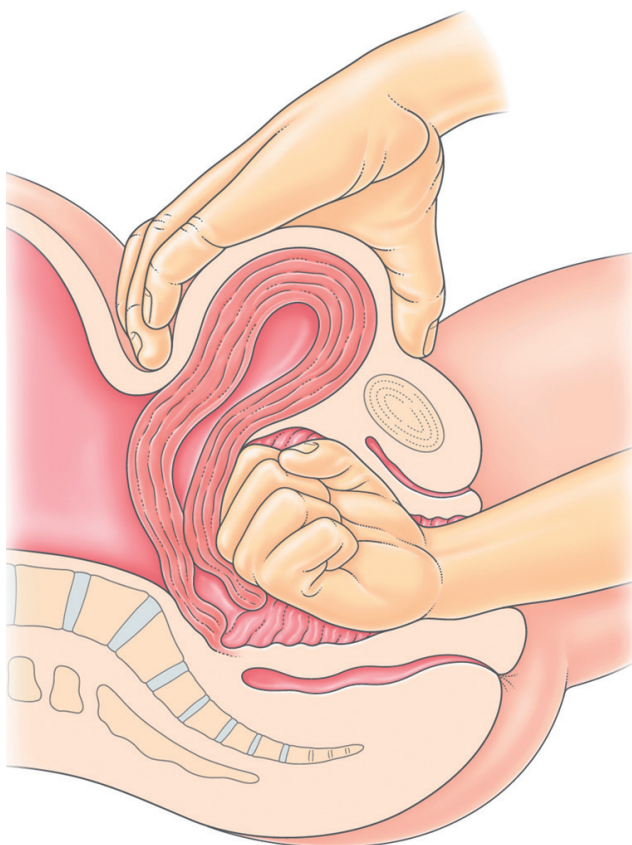
First, there is significant increase in cardiac output in pregnancy in accordance with red cell mass and plasma volume, which provides a compensative reserve for acute blood loss and hemostatic response following massive hemorrhage<sup>14</sup>. Second, the arrangement of the uterine muscle fibers, vis-à-vis the course of the uterine arteries, facilitates the use of compression techniques for effective control of postpartum hemorrhage and, finally, conservative treatment such as bimanual compression of the uterus may control blood loss (Figure 1), whilst intensive resuscitative measures are undertaken according to established labor ward protocols, which involve the anesthetists, hematologists, the obstetric team and intensive care support (see Chapters 36 and 40).

## NEW DEVELOPMENTS IN THERAPEUTIC OPTIONS

The type of surgical intervention depends upon several factors, paramount of which is the experience of the surgeon. Other factors include parity and desire for future children, the extent of the hemorrhage, the general condition of the patient and place of confinement. Women at high risk of postpartum hemorrhage should not be delivered in isolated units or units ill-equipped to manage sudden, life-threatening emergencies. Immediate access to specialist consultant care, blood products and intensive care are essential.

**Table 1** Common causes of postpartum hemorrhage

<i>Pre-existing conditions</i>	<i>Uterine overdistention, atony and disseminated intravascular coagulation (DIC)</i>	<i>Disorders of placenta, uterine and genital tract trauma</i>
Thrombocytopenic purpura	Polyhydramnios	Acute uterine inversion
Hypertensive disease	Multiple gestation	Lower segment cesarean section
Uterine myoma	Macrosomia	Operative vaginal delivery
Anticoagulation therapy	Prolonged labor	Precipitate delivery
Coagulation factor deficiency	Chorionamnionitis	Previous uterine surgery
Systemic disease of hemorrhagic nature	Tocolytic agents	Internal podalic version
Consumptive coagulopathy	Halogenated anesthetic agents	Breech extraction
Müllerian malfunction	High parity	Mid-cavity forceps
Anemia	Abruptio placentae	Obstructed labor
	Courvilliar's uterus	Abnormal fetal presentation
	Placenta previa	Vacuum site extraction
	Placenta accreta, increta, percreta	Placental subinvolution
		Retained products of conception
		Ruptured uterus



© Copyright B-Lynch '05

**Figure 1** Bimanual compression of the uterus, illustrating the first-line approach to mechanical hemostasis. This in itself might control bleeding significantly by assisting the uterus to use its anatomical and physiological properties such as the cross-over interlinked network of myometrial fibers for vascular compression and bleeding control. The patient should be placed in stirrups or frog-legged position in the labor ward or in theater whilst intravenous fluid and/or appropriate blood product runs freely. In some cases and commonly so, there may be failure to achieve satisfactory and lasting hemostasis by this method

### The B-Lynch suture compression technique

The procedure was first performed and described by Mr Christopher B-Lynch, a consultant obstetrician, gynecological surgeon, Fellow of the Royal College of Obstetricians and Gynaecologists of the UK and Fellow of the Royal College of Surgeons of Edinburgh, based at Milton Keynes General Hospital National Health Service (NHS) Trust (Oxford Deanery, UK), during the management of a patient with a massive postpartum hemorrhage in November 1989. This patient refused consent to an emergency hysterectomy<sup>3</sup>! Table 2 provides an audit summary of five case histories of other patients with severe life-threatening postpartum hemorrhage managed with this technique.

### The principle

The suture aims to exert continuous vertical compression on the vascular system. In the case of postpartum hemorrhage from placenta previa, a transverse lower segment compression suture is effective.

### The technique<sup>2-4</sup>

See Figures 2a (i and ii), 2b and 2c.

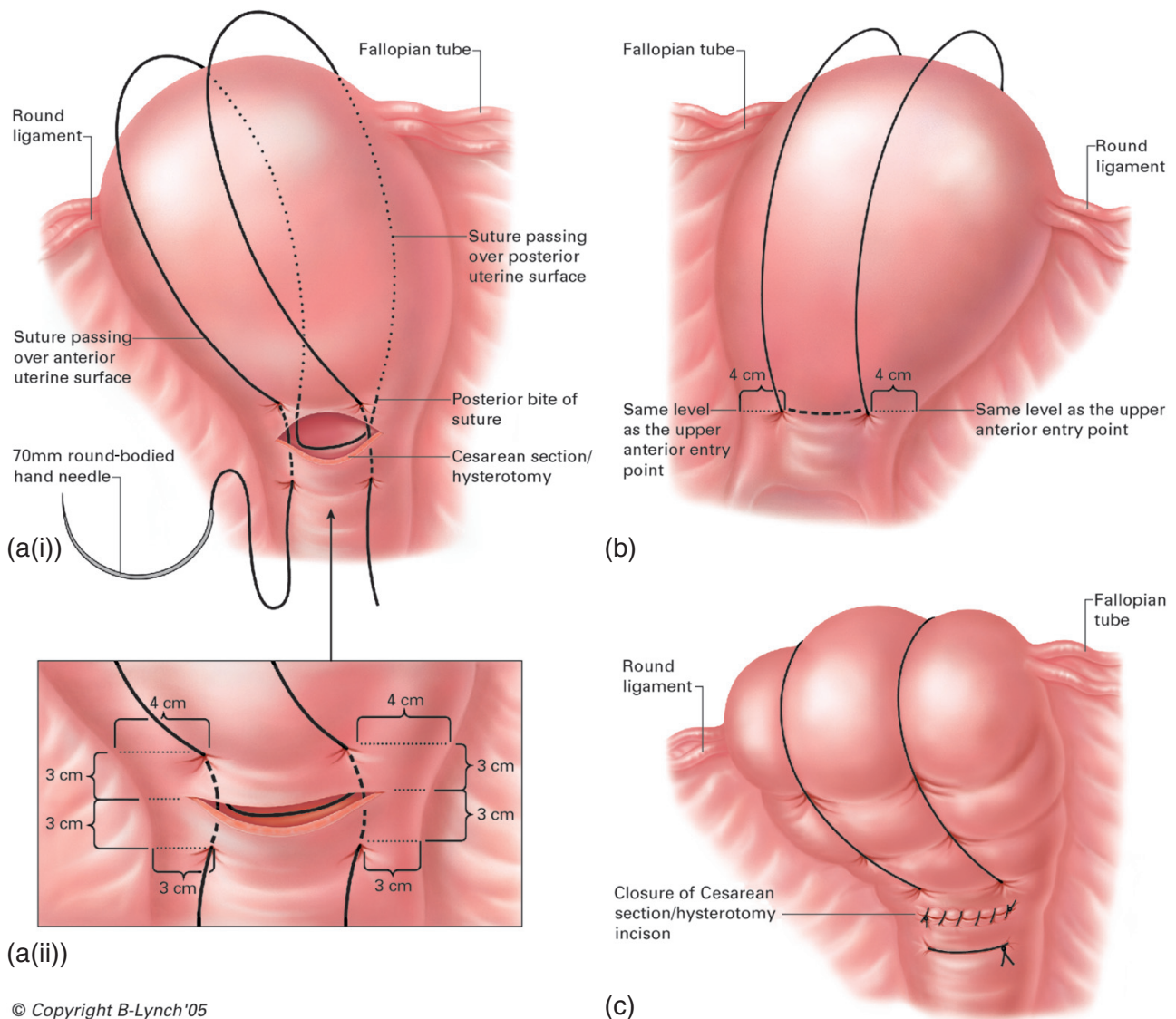
*Surgeon's position* In outlining the steps involved, we assume that the surgeon is right-handed and standing on the right-hand side of the patient. A laparotomy is always necessary to exteriorize the uterus. A lower segment transverse incision is made or the recent lower segment cesarean section suture (LSCS) removed to check the cavity for retained placental fragments and to swab it out.

*Test for the potential efficacy of the B-Lynch suture before performing the procedure* The patient is placed in the Lloyd Davies or semi-lithotomy position (frog leg). An assistant stands between the patient's legs and intermittently swabs the vagina to determine the presence and extent of the bleeding. The uterus is then exteriorized and bimanual compression performed. To do this, the bladder peritoneum is reflected inferiorly to a level below the cervix (if it has been taken down for a prior LSCS, it is pushed down again). The whole uterus is then compressed by placing one hand posteriorly with the ends of the fingers at the level of the cervix and the other hand anteriorly just below the bladder reflection. If the bleeding stops on applying such compression, there is a good chance that application of the B-Lynch suture will work and stop the bleeding.

Even in the presence of coagulopathy, bimanual compression will control diffuse bleeding points. If this test is successful, the application of the suture will also succeed. However, application of the B-Lynch suture is not a substitute for the medical treatment of coagulopathy, which should take place along with the operative intervention (see Chapter 25).

*Suture application* Given that the test criteria for the B-Lynch suture placement are met, the uterus remains exteriorized until application of the suture is complete. The senior assistant takes over in performing compression and maintains it with two hands during the placement of the suture by the principal surgeon.

- (1) *First stitch relative to the low transverse cesarean section/hysterotomy wound.* With the bladder displaced inferiorly, the first stitch is placed 3 cm below the cesarean section/ hysterotomy incision on the patient's left side and threaded through the uterine cavity to emerge 3 cm above the upper incision margin approximately 4 cm from the lateral border of the uterus (Figure 2a(i)).
- (2) *The fundus* The suture is now carried over the top of the uterus and to the posterior side. Once situated over the fundus, the suture should be more or less vertical and lie about 4 cm from the cornu. It does not tend to slip laterally toward the broad ligament because the uterus has been compressed and the suture milked through, ensuring that proper placement is achieved and maintained (Figure 2a).



© Copyright B-Lynch'05

**Figure 2** Summary of the application of the B-Lynch procedure

- (3) *The posterior wall* The location on the posterior uterus where the suture is placed through the uterine wall is actually easy to surface mark posteriorly. It is on the horizontal plane at the level of the uterine incision at the insertion of the uterosacral ligament (Figure 2b).
- (4) *Role of the assistant* As the operation proceeds, the assistant continues to compress the uterus as the suture is fed through the posterior wall into the cavity. This will enable progressive tension to be maintained as the suture begins to surround the uterus. Assistant compression will also help to pull the suture material through to achieve maximum compression, without breaking it, at the end of the procedure. Furthermore, it will prevent suture slipping and uterine trauma. The suture now lies horizontally on the cavity side of the posterior uterine wall.
- (5) *The fundus* As the needle pierces the uterine cavity side of the posterior wall, it is placed over the posterior wall, bringing the suture over the top of the fundus and onto the anterior right side of the uterus. The needle re-enters the cavity exactly in the same way as it did on the left side, that is 3 cm above the upper incision and 4 cm from the lateral side of the uterus through the upper incision margin, into the uterine cavity and then out again through 3 cm below the lower incision margin (Figure 2a(ii)).
- (6) *Later role of the assistant* The assistant maintains the compression as the suture material is milked through from its different portals to ensure uniform tension and no slipping. The two ends of the suture are put under tension and a double throw knot is placed for security to maintain tension after the lower segment incision has been closed by either the one- or two-layer method.
- (7) *Relation to the hysterotomy incision* The tension on the two ends of the suture material can be maintained while the lower segment incision is closed, or the knot can be tied first, followed by closure of the lower segment (Figure 2c). If the latter option

**Table 2** Audit summary of five selected case histories of patients with severe life-threatening postpartum hemorrhage treated by ecbolics and the B-Lynch brace suture application in the period 1989–1995 at Milton Keynes General Hospital, UK<sup>2</sup>

Age (years)	Parity	GA	Presenting diagnosis	Mode of delivery	Infant sex and weight (g)	Apgar score at 5 and 10 min	Type of PPH	Treatment and volume transfused	Intensive care admission	Outcome
28	PP	39/40	placental abruption, PPH, DIC	spontaneous vertex	male (2800)	4, 7	primary	ecbolics, 20 units fresh blood, 8 units FFP	48 h; full antibiotic cover	good; 3 years later spontaneous vertex delivery; female (3890 g); no problems
22	PP	43/40	prolonged labor, persisting occipito position?, cephalopelvic disproportion	emergency CS	male (4190)	7, 10	primary	ecbolics, 13 units blood, 5 units packed cells, BSA	48 h; full antibiotic cover	good; normal CT pelvimetry 2 years later; elective CS at 39 weeks; female (3820 g); no problems
23	PP (twin)	37/40	eclampsia in labor, PPH, DIC	emergency CS	(1) female (2735), (2) female (2430)	(1) 3, 8 (2) 5, 8	primary	ecbolics, 19 units blood, 5 units FFP, BSA	72 h; full antibiotic cover	good; no complications
35	PP (IVF)	38/40	major placenta previa	elective CS	female (3370)	9, 10	secondary, 9th day readmission	ecbolics, 15 units blood, 5 units FFP, BSA	72 h; full antibiotic cover	good; no complications
30	PP	40/40	uterine atony	spontaneous vertex	female (3890)	9, 10	primary	ecbolics, 15 units blood, 7 units packed cells, BSA	48 h; full antibiotic cover	good; no complications

PP, primiparous; GA, gestational age in weeks; PPH, postpartum hemorrhage; CS, cesarean section; CT, computerized tomography; DIC, disseminated intravascular coagulations; BSA, brace suture application; IVF, *in vitro* fertilization; FFP, fresh frozen plasma

\*Refused consent to emergency hysterectomy

is chosen, it is essential that the corners of the hysterotomy incision be identified and stay sutures placed before the knot is tied. This ensures that, when the lower segment is closed, the angles of the incision do not escape it. Either procedure works equally well. It is important to identify the corners of the uterine incision to make sure no bleeding points remain unsecured, particularly when most of these patients are hypotensive with low pulse pressure at the time of the B-Lynch suture application.

- (8) *Post-application and hysterotomy closure* It is probable that the maximum effect of suture tension lasts for only about 24–48 h. Because the uterus undergoes its primary involutionary process in the first week after vaginal or cesarean section delivery, the suture may have lost some tensile strength, but hemostasis would have been achieved by that time. There is no need for delay in closing the abdomen after the application of the suture. The assistant standing between the patient's legs swabs the vagina again and can confirm that the bleeding has been controlled.

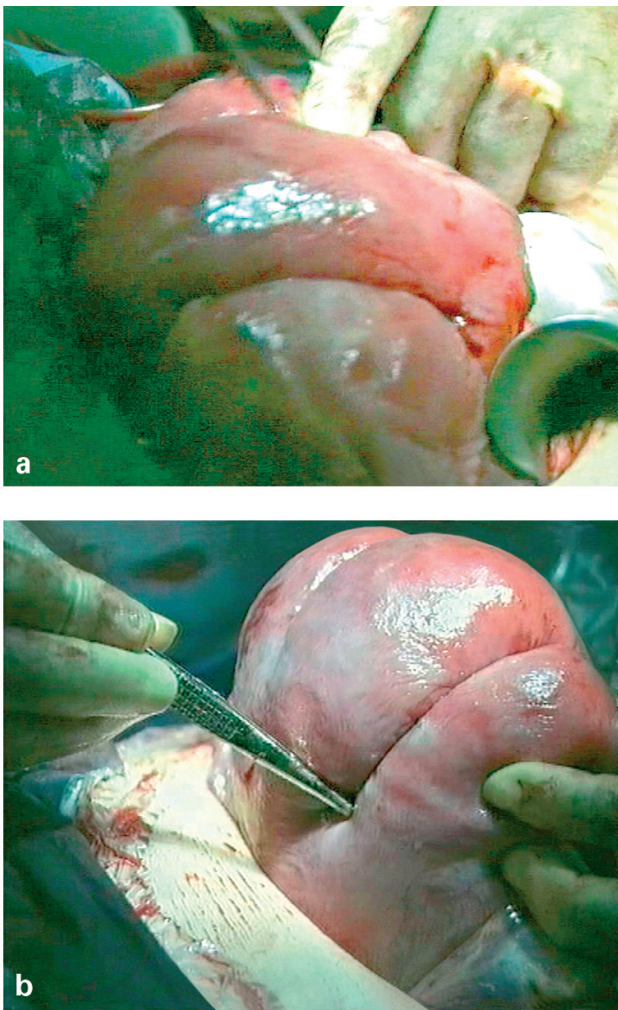
*Application after normal vaginal delivery* If laparotomy is required for the management of atonic postpartum hemorrhage, hysterotomy is necessary to apply the B-Lynch suture. Hysterotomy will also allow exploration of the uterine cavity, exclude retained products of conception, evacuate large blood clots and diagnose abnormal placentation and decidual tears, damage and

bleeding. B-Lynch suture application or any modification of it (see below) without hysterotomy or re-opening of the cesarean section wound runs the potential risk of secondary postpartum hemorrhage. Therefore, confirmation that the uterine cavity is completely empty is essential. Furthermore, hysterotomy ensures that the correct application of the suture provides maximum and even distribution of the compressive effect during and after application of the B-Lynch suture (Figures 2 and 3). Also, it avoids blind application of the suture and the possibility of obliteration of the cervical and/or uterine cavities that may lead to clot retention, infected debris, pyometria, sepsis and morbidity<sup>3,11,12,15</sup>.

*Application for abnormal placentation* The B-Lynch suture may be beneficial in cases of placenta accreta, percreta and increta. In a patient with placenta previa, a figure-of-eight or transverse compression suture to the lower anterior or posterior compartment or both is applied to control bleeding. If this is not completely successful, then, in addition, the longitudinal Brace suture component may be applied for further/complete hemostasis<sup>3</sup>.

## POSTOPERATIVE FOLLOW-UP

Three patients from the original series had laparoscopy postoperatively for sterilization, suspected pelvic inflammatory disease or appendicitis. One patient who



© Copyright B-Lynch '06

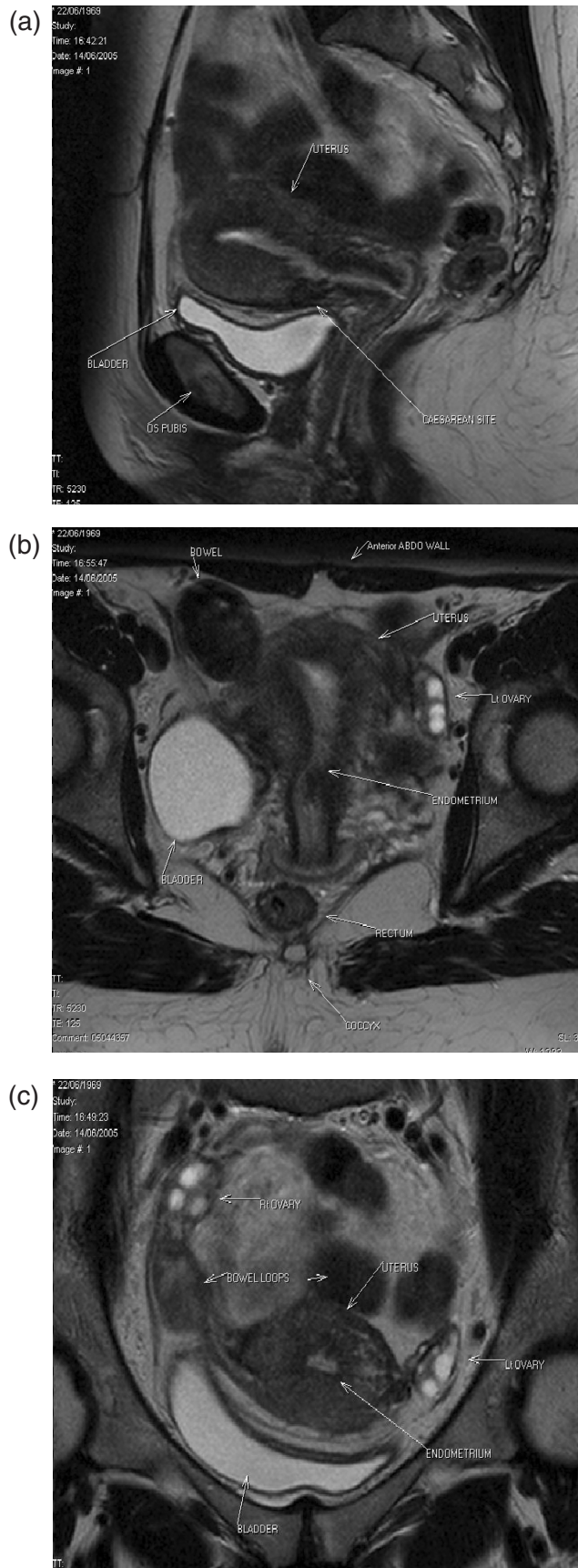
**Figure 3** The *in vivo* effect of correct application of the B-Lynch surgical technique seen immediately after successful suture application. No congestion, no ischemia and no 'shouldering' of the sutures at the fundus

had a history of ileostomy for surgical reasons had laparotomy 10 days after her B-Lynch suture for suspected intestinal obstruction (unpublished data, B-Lynch). Magnetic resonance imaging and hysterosalpingography were performed on one patient, showing no intraperitoneal or uterine sequelae<sup>16</sup> (Figure 4a-c). No complications have been observed in the five patients of the first published series<sup>2</sup> (see Table 1). Moreover, all have succeeded in further pregnancy and delivery<sup>17,18</sup>.

Tables 3–5 lists the clinical points of the B-Lynch surgical technique, the Hayman uterine compression suture (see Figure 5) and the Cho multiple square sutures (see Figure 6).

**WORLD-WIDE REPORTS**

The current level of application of the B-Lynch suture world-wide includes over 1300 successful cases; of these, there are only 19 failures. The Indian subcontinent has the largest number of reported successful applications, over 250, followed by Africa, South



**Figure 4** Normal MRI 6 months after massive postpartum hemorrhage treated by B-Lynch surgical technique followed by uneventful spontaneous vertex vaginal delivery 22 months later. (a) Sagittal view showing normal endometrial cavity and treated cesarean incision site; (b) coronal view, with no uterine cavity synechiae<sup>19</sup>; (c) view at level of incision for cesarean section, showing well-healed features

**Table 3** The B-Lynch surgical technique: clinical points

1. User-friendly suture material monocril No.1 mounted on 90-cm curved ethigard blunt needle (code W3709) (Ethicon, Somerville, NJ). Other rapidly absorbable sutures can be used according to the surgeon's preference. A good length and needle are essential<sup>19</sup>
2. Basic surgical competence required
3. Uterine cavity checked, explored and evacuated
4. Suture bends maintain even and adequate tension without uterine trauma or 'shouldering'
5. Allows free drainage of blood, debris and inflammatory material
6. Transverse compression suture applied to the lower segment for abnormal placentation effectively controls bleeding
7. Simple, effective and cost-saving
8. Fertility preserved and proven<sup>3</sup>
9. Mortality avoided<sup>3</sup>
10. World-wide application and successful reports (> 1300) (B-Lynch, personal data base, christopherbl@aol.com)
11. Potential for prophylactic application at cesarean section when signs of imminent postpartum hemorrhage develop, e.g. placenta accreta, or where blood transfusion is declined, e.g. placenta previa surgery on a Jehovah's Witness

**Table 4** The Hayman uterine compression suture: clinical points

1. Lower uterine segment or uterine cavity not opened
2. Uterine cavity not explored under direct vision
3. Probably quicker to apply
4. No feed-back data on fertility outcome
5. Morbidity feed-back data limited
6. Unequal tension leads to segmented ischemia secondary to slippage of suture – 'shouldering' with venous obstruction

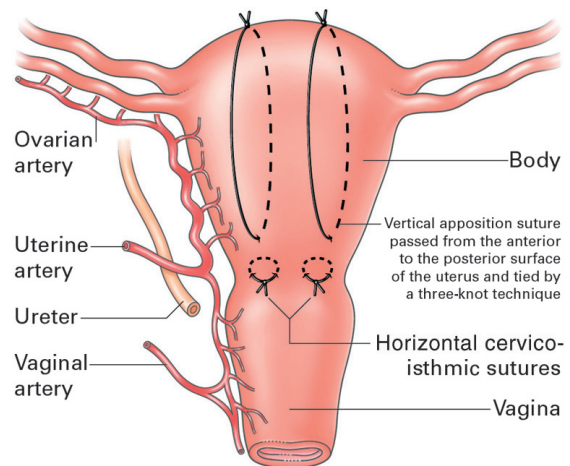
**Table 5** The Cho multiple square sutures: clinical points

1. Multiple full-thickness square sutures applied, probably time-consuming if many square sutures required
2. Uterine cavity drainage restriction – pyometra risk<sup>15</sup>
3. No feed-back data on fertility outcome
4. Morbidity feed-back data limited
5. Rhythmic contraction not facilitated and involution impeded
6. The production of multiple uterine senescentiae (see Chapter 28)

America, North America, Europe and other countries. The 17 reported failures were because of delay in application, poor technique, defibrination and inappropriate material. Various suture materials have been used. However, the monocril suture (code WC3709) is recommended because it is user- and tissue-friendly with uniform tension distribution and is easy to handle<sup>20</sup>. Holtsema and colleagues recently opined, in a review, that the B-Lynch technique for postpartum hemorrhage should be an option for every gynecologist<sup>21</sup>. Wohlmuth and colleagues published outcome of a large series with a 91% success rate (world-wide cumulative success rate 98%)<sup>22</sup>.

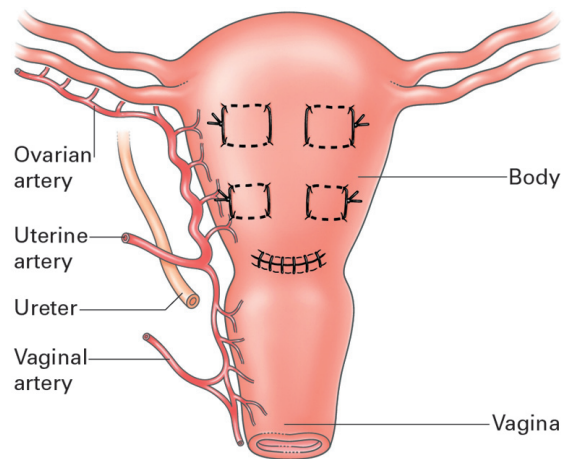
**CONCLUSION**

Of the compression suturing techniques described above, the B-Lynch procedure has been recommended by the 2000–2002 Triennial Confidential Enquiry into Maternal Deaths in the United Kingdom<sup>23</sup>, The Royal College of Obstetricians and Gynaecologists in the UK, and the Cochrane Database of systematic reviews. To date, no serious adverse outcomes have been associated with the B-Lynch surgical technique<sup>3,17,20,22,24</sup>. Furthermore, the latest 2000–2002 Triennial Confidential Enquiry states that no deaths were reported in women who had had



© Copyright B-Lynch'05

**Figure 5** The Hayman uterine compression suture without opening the uterine cavity<sup>11</sup>



© Copyright B-Lynch'05

**Figure 6** The Cho multiple square sutures compressing anterior to posterior uterine walls<sup>12</sup>

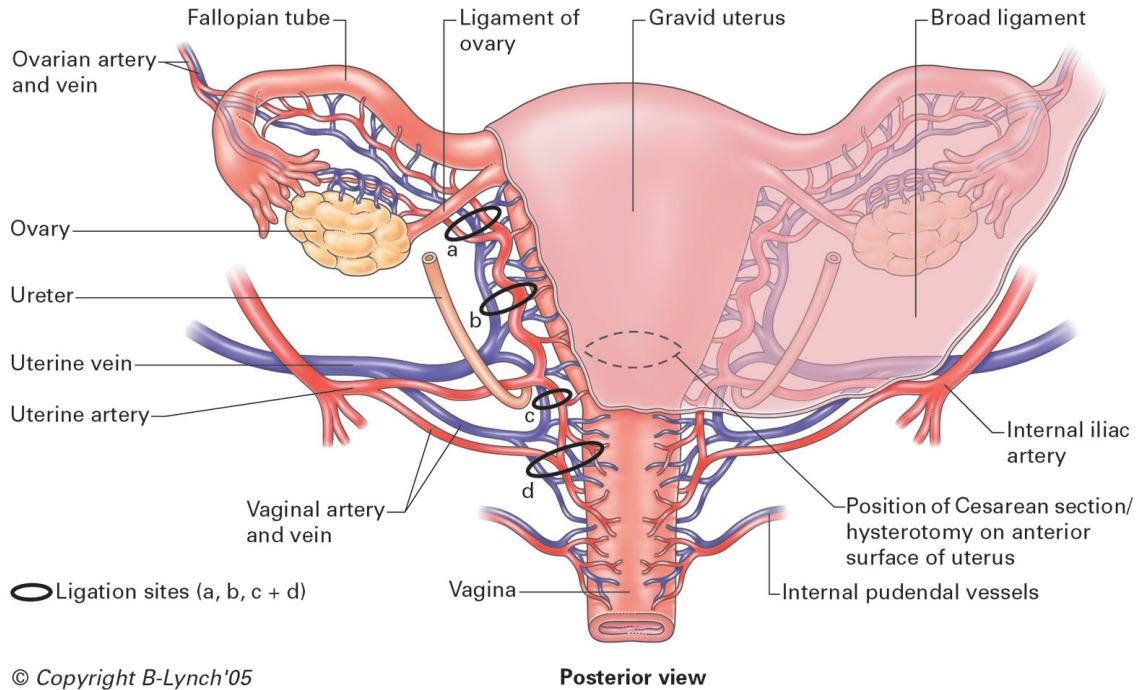
interventional radiology or B-Lynch suture in the management of postpartum hemorrhage<sup>23</sup>.

It is important to remember that, if a patient is a known or appreciated risk for postpartum hemorrhage, then the elective delivery should be performed in the day time, with prearranged co-operation between the imaging department and the obstetric

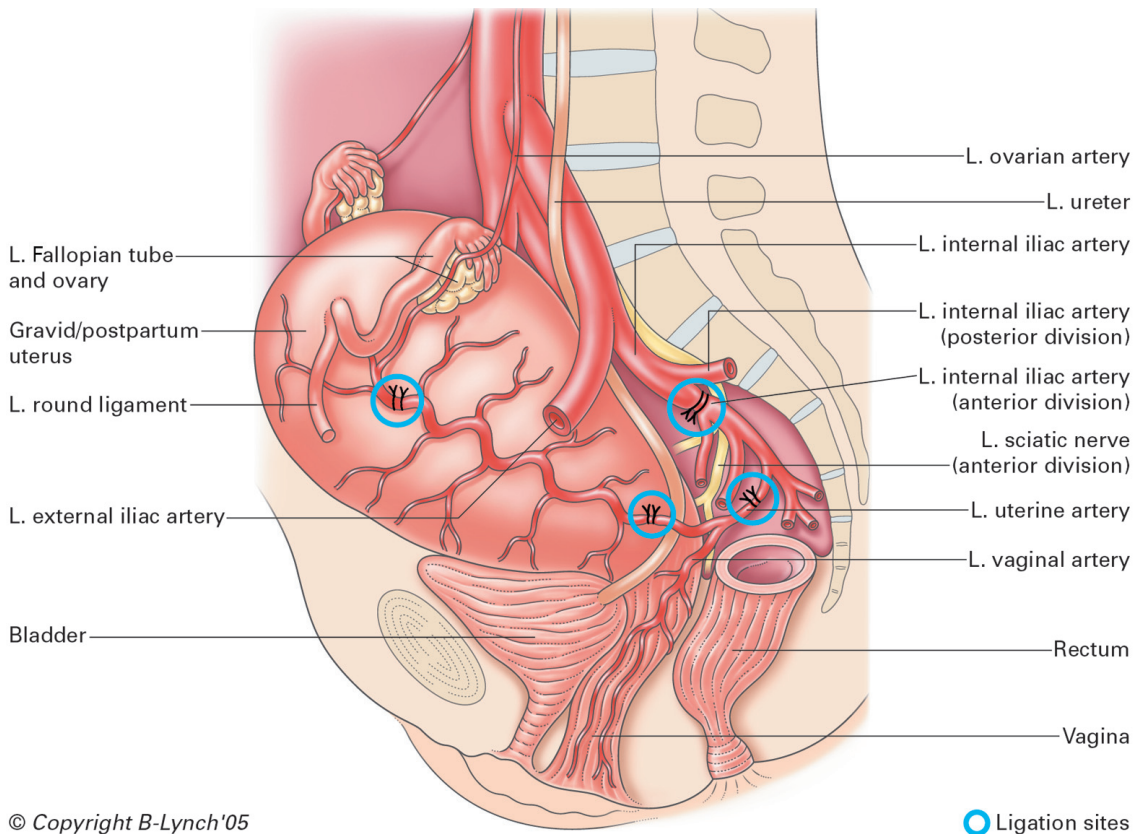
team. Theater staff should be alerted in time so that conservative surgery can be carried out quickly if needed. Patients at particular risk are those with obesity, cardiomyopathy, coagulopathy, abnormal placentation, polyhydramnios and specific religious convictions contraindicating blood transfusion.

### PLACEMENT OF LIGATURES IN STEPWISE DEVASCULARIZATION

The essential requirements are not simple and may not be available in every unit. First, there is a need for a competent obstetrician who is conversant and competent at pelvic gynecological procedures, and who has a



**Figure 7** Placement of ligatures in the process of stepwise devascularization, including ligation of the descending uterine and vaginal arteries



**Figure 8** The complex vascular distribution to the pelvic organs. In this procedure of stepwise devascularization, the patient must be in the Lloyd Davis or modified lithotomy position, with one of the assistants able to access and swab the vagina to assess bleeding control

working knowledge of the pelvic anatomy, including the vascular and neurological supply of the pelvic organs. Second, there is a need for an obstetric anesthetist, as well as a vascular and/or gynecological cancer surgeon on standby. Finally, provisions must be available for admission postoperatively to the intensive care unit.

This set of requirements takes full account of the extraordinarily generous blood supply to the uterus and the pelvic organs (see Figure 7). The surgical approach starts with ligation of the uterine artery and its distribution to the uterus, preferably as it emerges from crossing over the ureter or as it approaches the uterine wall to penetrate and establish its division<sup>25</sup>. This could be carried out unilaterally or bilaterally about 2 cm from the uterine angle at cesarean section or where the lower segment is opened after conservative surgery for postpartum hemorrhage has failed (Figure 8).

It is absolutely essential to remember that the internal iliac (hypogastric artery) gives off independent branches that descend to the cervix and vagina (vaginal branch), respectively (see Chapter 52). Devascularization can be achieved by independent ligation sutures applied bilaterally to the cervix and/or vagina. The ovarian vascular supply to the uterus is also ligated, either unilaterally or bilaterally. Unilateral or bilateral ligation of the internal iliac artery may become necessary as a further step to control massive postpartum hemorrhage. A skilful surgeon should aim to ligate the anterior division of the internal iliac artery in order to achieve further devascularization of the uterus without compromising blood supply to the posterior division. However, ligation of the internal iliac directly could be done unilaterally or bilaterally without devascularizing the pelvic organs<sup>8,26</sup>. This may save time, life and organ.

## References

1. Drife J. Management of primary post partum haemorrhage. *Br J Obstet Gynaecol* 1997;104:275-7
2. B-Lynch C, Coker A, Lawal AH, Cowen MJ. The B-Lynch surgical technique for the control of massive post partum hemorrhage: an alternative to hysterectomy? Five cases reported. *Br J Obstet Gynaecol* 1997;104:372-5
3. B-Lynch C, Cowen M.J. A new non-radical surgical treatment of massive post partum hemorrhage. *Contemp Rev Obstet Gynaecol* 1997; March:19-24
4. Chez RA, B-Lynch C. The B-Lynch suture for control of massive post partum hemorrhage. *Contemp Obstet Gynaecol* 1998;43:93-8
5. Day LA, Mussey RD, DeVoe RW. The intrauterine pack in the management of post partum hemorrhage. *Am J Obstet Gynecol* 1948;55:231-43
6. Bobrowski RA, Jones JB. A thrombogenic uterine pack for post partum hemorrhage. *Obstet Gynecol* 1995;85:836-7
7. Waters EG. Surgical management of postpartum hemorrhage with particular reference to ligation of uterine arteries. *Am J Obstet Gynecol* 1952;64:1143-8
8. Evans S, McShane P. the efficacy of internal iliac artery ligation in obstetric hemorrhage. *Surg Gynaecol Obstet* 1985; 160:250-3
9. Abdrabbo SA. Step-wise uterine devascularization: a novel technique for management of uncontrollable post partum hemorrhage with the preservation of the uterus. *Am J Obstet Gynecol* 1999;171:694-700
10. Baskett TF. Surgical management of severe obstetric hemorrhage: experience with an obstetric hemorrhage equipment tray. *J Obstet Gynaecol Can* 2004;26:805-8
11. Hayman RG, Arulkumaran S, Steer PJ. Uterine compression sutures: surgical management of post partum hemorrhage. *Obstet Gynecol* 2002;99:502-6
12. Cho JH, Jun HS, Lee CN. Hemostatic suturing technique for uterine bleeding during cesarean delivery. *Obstet Gynecol* 2000;96:129-31
13. Roman A, Rebarbar A. Seven ways to control post partum haemorrhage. *Contemp Obstet Gynaecol* 2003;48:34-53
14. WHO Report of Technical Working Group. The Prevention and Management of Post Partum Haemorrhage. Geneva: World Health Organisation, 1999;WHO/MCH/90-7
15. Ochoa M, Allaire AD, Stitely ML. Pyometra after hemostatic square suture technique. *Obstet Gynecol* 2002;99:506-9
16. Ferguson JE, Bourgeois FJ, Underwood PB, B-Lynch C. Suture for post partum hemorrhage. *Obstet Gynecol* 2000;95: 1020-2
17. El-Hammamy E, B-Lynch C. A worldwide review of the uses of the uterine compression suture techniques as alternative to hysterectomy in the management of severe postpartum haemorrhage. *J Obstet Gynaecol* 2005;25:143-9
18. Tsitpakidis C, Lalonde A, Danso D, B-Lynch C. Long term anatomical and clinical observations of the effects of the B-Lynch uterine compression suture for the management of post partum hemorrhage – ten years on. *J Obstet Gynaecol* 2006; in press
19. Wu HH, Yeh GP. Uterine cavity synechiae after hemostatic square suturing technique. *Obstet Gynecol* 2005;105: 1176-8
20. Price N, B-Lynch C. Technical description of the B-Lynch suture for treatment of massive hemorrhage and review of published case. *Int J Fertil Womens Med* 2005;50:148-63
21. Holtsema H, Nijland R, Huisman A, Dony J, van den Berg PP. The B-Lynch technique for post partum haemorrhage: an option for every gynaecologist. *Eur J Obstet Gynaecol Reprod Biol* 2004;115:39-42
22. Wohlmuth C, Gumbs J, Quebral-Ivie J. B-Lynch suture, a case series. *Int J Fertil Womens Med* 2005;50:164-73
23. Department of Health. Why Mothers Die: Report on Confidential Enquiries into Maternal Deaths in the United Kingdom 2000-2002 Triennial Report. London: RCOG Press, 2004: 94-103
24. Allam MS, B-Lynch C. The B-Lynch and other uterine compression suture techniques. *Int J Gynaecol Obstet* 2005;89: 236-1
25. O'Leary JA. Uterine artery ligation in the control of post-caesarean hemorrhage. *J Reprod Med* 1995;40:189-93
26. Clarke SL, Koonings P, Phelan JP. Placenta accreta and prior cesarean section. *Obstet Gynecol* 1985;66:89-92