

Ultrasound Imaging for Pediatric Anesthesia: A Review

Santhanam Suresh MD, Lauren J Taylor BA and Amar S. Minhas
*Department of Pediatric Anesthesiology, Children's Memorial Hospital,
Northwestern University Feinberg School of Medicine, Chicago, IL
USA*

1. Introduction

There has been a recent increase in the use of regional anesthesia in pediatric patients (Lacroix, 2008). This explosive growth, particularly in the use of truncal blocks, can be attributed in part to the refinement of anatomically based ultrasound imaging to facilitate nerve localization. Historically, pediatric regional anesthesia has posed a significant challenge due to the close proximity of nerves to critical structures and the need for limiting the local anesthetic volume below toxic levels in children. Ultrasound guidance, however, allows the visualization of important anatomy and can help overcome many of these traditional obstacles.

This chapter will review a variety of common peripheral nerve and central neuraxial blocks that can be performed using ultrasound guidance in children. This aspect of regional anesthesia has the potential for significant contributions to evidence-based medicine. Because ultrasound guidance is a relative newcomer to the field of regional anesthesia, most of the current literature is not evidence based. As a result, much of the data comes from case reports and case series. This chapter is based on an extensive review of the literature using MEDLINE and EMBASE from 1980 to May 28, 2009. Our goal is to provide the pediatric anesthesiologist with a comprehensive summary of the relevant sonoanatomy, techniques, and outcomes of ultrasound guidance for peripheral nerve blocks of the extremities and trunk as well as neuraxial blocks in pediatric patients based on currently available literature.

2. Peripheral nerve blocks

2.1 Upper extremity blocks

Peripheral regional anesthesia is of great utility in children undergoing surgery on the upper extremities. Although many approaches to the brachial plexus have been described, the axillary block using conventional methods is still the most commonly performed and reported brachial plexus blockade in children. This may be due to the fact that other block sites are situated near critical structures such as the cervical pleura (supraclavicular and infraclavicular) and the spinal cord (interscalene). Although there is a paucity of related literature, the introduction of ultrasound imaging will likely greatly increase the performance of brachial plexus blocks in infants and children at locations besides the commonly described axillary approach by allowing for real-time visualization of anatomical structures.

2.1.1 Axillary block

2.1.1.1 Sonoanatomy

The axillary approach blocks the radial, median and ulnar nerves. A probe placed perpendicular to the anterior axillary fold provides a short-axis view of the neurovascular bundle with the biceps brachii and coracobrachialis muscles lateral and the triceps brachii medial and deep to the biceps. The axillary artery is a useful ultrasound landmark and appears as a circular anechoic structure adjacent to the biceps and coracobrachialis muscles. Terminal nerves surround the artery with the radial nerve located deep and along the midline of the artery. The median and ulnar nerves are both superficial to the artery, with median nerve visible between the artery and biceps muscle while the ulnar nerve is found more medial (Figure 1). It is important to be aware of anatomic variation, particularly in the location of the median nerve. The musculocutaneous nerve is located between the coracobrachialis and biceps muscles, but it is difficult to detect in children (Rapp & Grau, 2004). In contrast to the textbook anatomical description, in an ultrasound image the radial, median, and ulnar nerves often appear the same size as the axillary artery (Rapp & Grau, 2004).

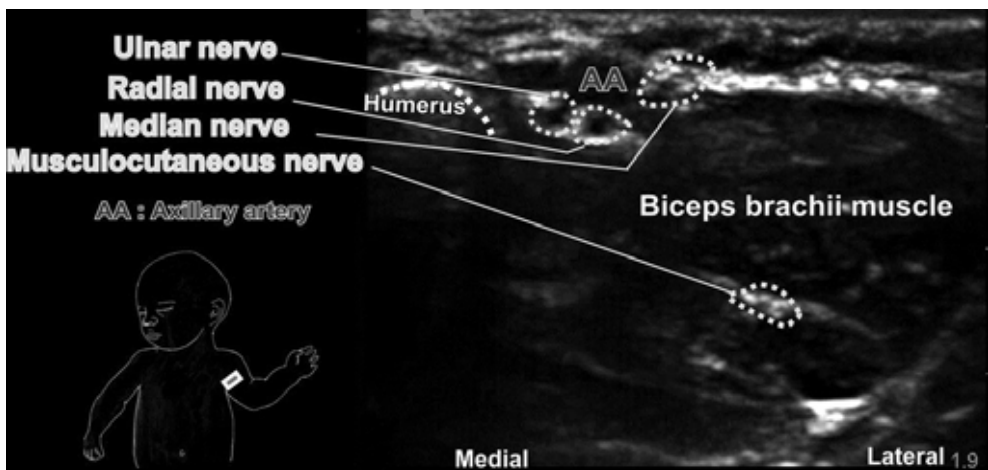


Fig. 1. Sonoanatomy of the axillary block location using a linear hockey stick probe (SLA 6-13 MHz, 25-mm footprint) placed transversely to the humerus.

2.1.1.2 Technique

An axillary block may be used for procedures on the elbow, forearm, or hand. The use of ultrasound guidance for this block in children, however, is not well described in the literature; a recent search produced no original reports (Fleischmann et al., 2003). This block may be performed in children using techniques borrowed from adult patients. With a hockey stick or linear small footprint probe placed proximally in the axilla and transverse to the humerus, an in-plane technique may be used. It is best to use multiple injections with needle redirections to ensure that the local anesthetic surrounds all the terminal nerves of the plexus. Due to the close proximity of the axillary vein and artery, multiple punctures may be necessary to avoid intravascular injection.

2.1.1.3 Outcome and discussion

In children, the axillary block is one of the most popular approaches to the brachial plexus (Cregg et al., 1996). Due to the abundance of vessels in the axillary region, caution must be taken when performing this block to avoid intravascular injection. This is particularly important when multiple punctures are required to achieve the desired circumferential local anesthetic spread. The use of ultrasound for real-time visualization may reduce this risk. Color Doppler is also a helpful tool to identify the axillary vasculature. Due to the superficial location of the plexus, ultrasound guidance may help the anesthesiologist guide the needle advancement (Tsui & Suresh, 2010a).

2.1.2 Interscalene block

2.1.2.1 Sonoanatomy

Ultrasound imaging allows visualization of the C5, C6, and C7 nerve roots between the anterior and middle scalene muscles (Figure 2). In a transverse oblique plane at the level of the cricoid cartilage and at the posteriolateral aspect of the sternocleidomastoid muscle, the muscle appears as a triangular shaped structure overlying the internal jugular vein and common carotid artery. The scalene muscles serve as useful landmarks; the anterior scalene lies deep to the sternocleidomastoid and lateral to the subclavian artery, while the middle and posterior scalenes are located more posterolaterally. The neurovascular (interscalene) sheath appears as a hyperechoic structure within the interscalene groove. The trunks and/or roots of the brachial plexus may be visible as round or oval-shaped hypoechoic structures.

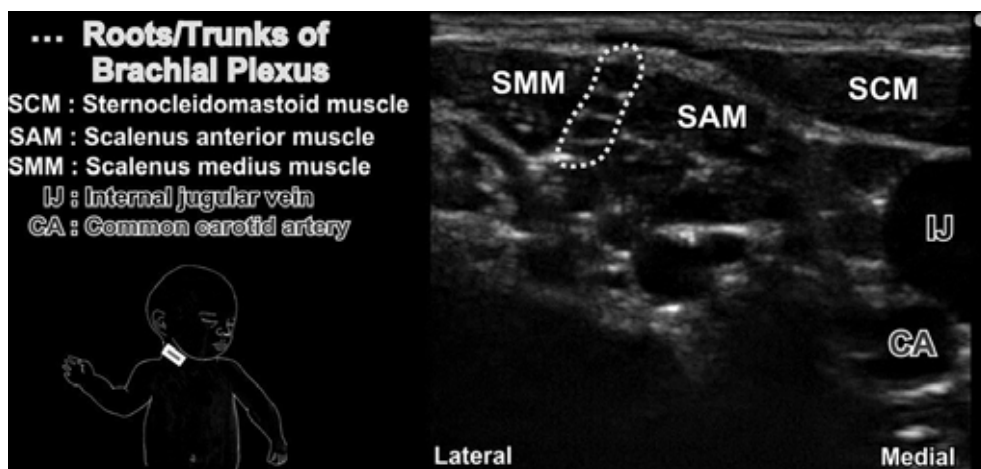


Fig. 2. Sonoanatomy at the interscalene groove using a linear hockey stick probe (SLA, 6-13 MHz, 25-mm footprint).

2.1.2.2 Technique

For optimal imaging, the probe is placed in a transverse oblique plane at the level of the cricoid cartilage. A combined ultrasound-guided nerve stimulating technique may facilitate nerve localization. Using an in-plane approach and slight redirections to advance the needle close to the brachial plexus, local anesthetic spread around the nerve roots or trunks may be

visualized. Precise needle placement may limit the dose of local anesthetic required (Tsui & Suresh, 2010a). This combined ultrasound guided-nerve stimulation technique has also been described in the literature using an out-of plane approach and displacement of the middle scalene muscle tissue as a means of tracking the needle tip (Fredrickson, 2007).

2.1.2.3 Outcome and discussion

An interscalene approach is a means of providing analgesia for patients undergoing surgery of the shoulder or proximal arm that can last 6-12 hours. This block may also be used for catheter placement for continuous analgesia (Marhofer et al, 2005). While it may be advantageous to use nerve stimulation in conjunction with ultrasound to confirm the identity of the localized nerve root, a report documenting the performance of an interscalene block in a 7-year-old child with femur fibula ulna syndrome suggests that ultrasound guidance may be of special value for patients in whom the use of nerve stimulation is impossible (Van Geffen et al., 2006).

Due to potential adverse effects including pneumothorax, vertebral artery injection, and intrathecal injection, the intrascalene block is not common in pediatrics. Palpation of the interscalene groove often proves challenging in children under general anesthesia and as a result a recent report states that this block is not recommended for any heavily sedated or anesthetized patient (Bernards et al., 2008). However, the improvements in nerve localization made possible due to ultrasound guidance have the potential to increase the use of this block in children.

2.1.3 Supraclavicular Block

2.1.3.1 Sonoanatomy

At the level of a supraclavicular approach, the trunks and divisions of the brachial plexus are superiolateral to the subclavian artery and above the first rib. This relationship is most clearly visualized with the probe in a coronal oblique plane. The subclavian artery may be used as a primary ultrasound landmark and appears as an anechoic, hypodense, pulsatile structure. Color Doppler may be useful to confirm vascular identification. The trunks and divisions of the plexus appear as three hypoechoic grape-like clusters around the artery while a hyperechoic line with dorsal shadowing indicates the first rib (Figure 3).

2.1.3.2 Technique

Literature describing the supraclavicular technique in children is limited (Suresh et al., 2009). A recent report describes an approach similar to that used in adult patients (De Jose Maria et al, 2008). With a high frequency probe in the coronal oblique plane, the plexus divisions and/ or roots are visible lateral to the subclavian artery. Using an in-plane approach, directing the needle from lateral to medial avoids vascular structures in contact with the plexus. An out-of plane approach may also be successful.

2.1.3.3 Outcome and discussion

The supraclavicular block may be performed for patients undergoing most procedures of the upper extremities. However, when compared to other brachial plexus blocks there is an increased risk of pneumothorax due to the proximity of the lung parenchyma at the level of this block. By using an in-plane approach, ultrasound guidance may reduce this risk by providing clear visibility of the needle shaft and tip, making the supraclavicular approach one of the most reliable and effective blocks of the brachial plexus (Tsui & Suresh, 2010a).

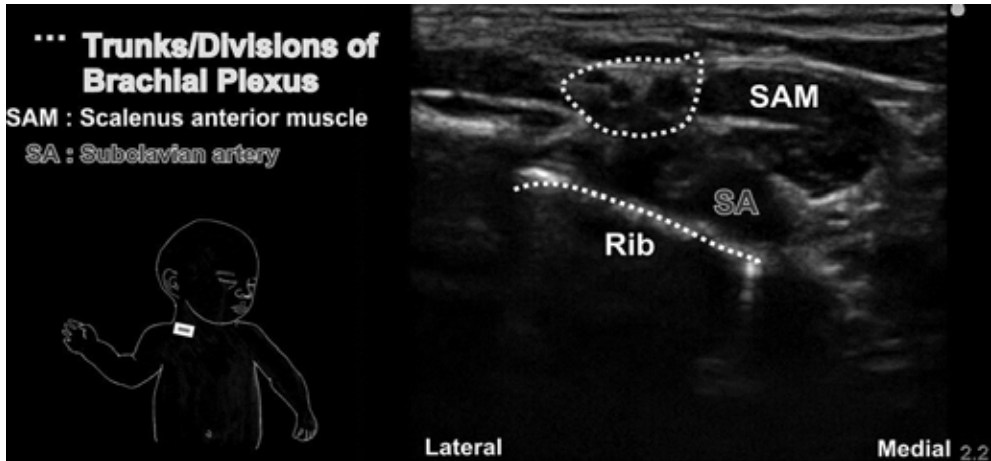


Fig. 3. Sonoanatomy at the supraclavicular block location using a linear hockey stick probe (SLA, 6-13 MHz, 25-mm footprint) placed in the coronal oblique plane.

2.1.4 Infraclavicular block

2.1.4.1 Sonoanatomy

In the infraclavicular approach to the brachial plexus, the cords are located inferior and medial to the coracoid process. Both the axillary artery and vein serve as useful ultrasound landmarks for the infraclavicular approach. These vessels are located deep and medial to the cords, with the vein positioned medial and caudal to the artery (Figure 4). Although all the cords surround the artery, they are not visualized with equal clarity. The lateral cord is most

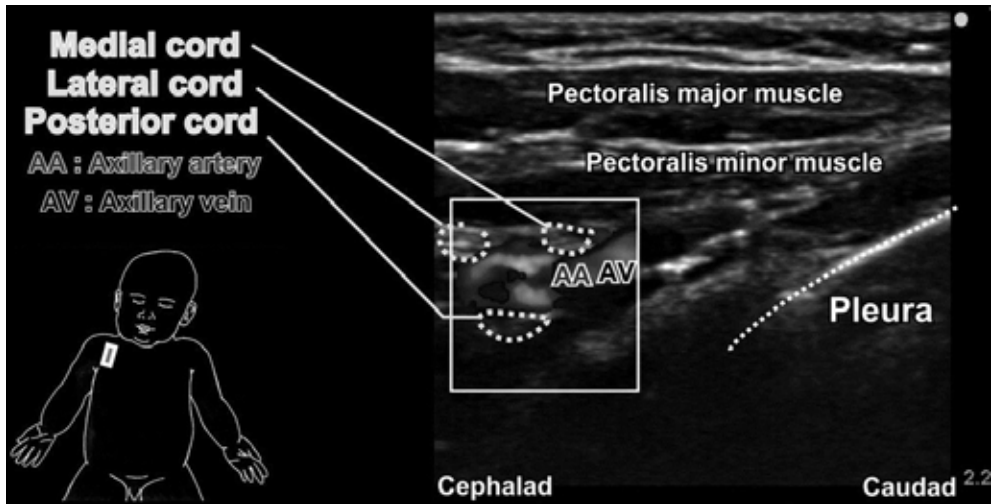


Fig. 4. Sonoanatomy at the infraclavicular block location using a linear hockey stick probe (SLA, 6-13 MHz, 25-mm footprint) placed below the clavicle in a parasagittal plane.

easily viewed and appears as a hyperechoic oval structure. In contrast, the posterior and medial cords may be difficult to visualize, in part because the view may be obstructed by the axillary vasculature; the medial cord lies between the artery and vein while the posterior cord is deep to the artery. The pectoralis major and minor muscles lie superficial to the neurovascular bundle and are separated by a hyperechoic lining (perimysium).

2.1.4.2 Technique

While the plexus lies quite deep in adults, the structure is much more superficial in children, making a higher frequency probe optimal. Marhofer *et al.* described a lateral approach to this block in which the probe was placed transversely below the clavicle with the patient in the supine position (Marhofer *et al.*, 2004). The authors achieved sufficient visualization of the plexus in all 40 patients studied. With the needle inserted using an out-of-plane approach 1 cm inferior to the probe, the local anesthetic dispersion was also clearly visualized.

A recent report by De Jøse Maria *et al.* described a different technique in which the probe was placed either parallel or in a slightly parasagittal plane to the clavicle (De Jøse Maria *et al.*, 2008). The authors recommended using a medium frequency probe to maximize visibility of deeper structures in older children. The needle was inserted cephalad to the probe and redirected when necessary to ensure optimal spread of the local anesthetic around the cords.

2.1.4.3 Outcome and discussion

The infraclavicular block is commonly used for patients undergoing surgery of the upper arm and elbow. It may also be a useful approach for placing a catheter in the posterior cord during more extensive procedures. The risks of this block are similar to the supraclavicular approach, with the danger of pneumothorax being most serious. Just as with the supraclavicular block, an in-plane needle insertion under ultrasound guidance may minimize the risk by allowing clear visualization of the needle tip and shaft (Chin *et al.*, 2008). In addition, due to the closer proximity of the cervical pleura to the plexus cords medially, a lateral puncture site is recommended (Greher *et al.*, 2002). Ultrasound imaging may also be advantageous in avoiding multiple puncture sites and visualizing underdeveloped structures like the coracoid process that may be difficult to palpate in children using “blind” techniques (Marhofer *et al.*, 2004; de Jøse Maria & Tielens, 2004).

The first controlled study by Marhofer *et al.* in 2004 compared ultrasound guidance to traditional nerve stimulation technique for performance of the infraclavicular block in children. The authors reported ultrasound guidance to be associated with superior visual analog scores during block puncture, better sensory onset times (mean times of onset were 9 vs. 15 mins), longer duration of sensory block, and better sensory and motor block scores 10 mins after the block was performed. The authors explained the faster onset and longer duration of the blocks by the more accurate deposition of local anesthetic possible under ultrasound guidance (Marhofer *et al.*, 2004). Although this study was a prospective, randomized controlled blinded study, the authors did not comment on the power necessary to determine statistical significance.

2.2 Lower extremity blocks

Multiple regional anesthesia techniques may be used for children undergoing surgery of the lower extremities, including lumbar plexus, femoral, and sciatic nerve blockades. These

procedures can be performed successfully with the aid of ultrasound, which allows clearer localization of structures as well as visual confirmation of the local anesthetic spread.

2.2.1 Lumbar plexus block

2.2.1.1 Sonoanatomy

Lumbar plexus blocks provide analgesia to the major branches of the lumbar plexus, including the femoral, genitofemoral, lateral femoral cutaneous, and obturator nerves and are therefore indicated for surgical procedures involving the hip, knee, or foot. In infants, a transverse (axial) view using a linear probe reveals several bony structures including spinous processes, laminae, and transverse processes, as well as musculature such as the erector spinae and quadratus lumborum. The plexus is located deep to these structures and is embedded in the psoas muscle (Figure 5). In a transverse scan, the spinous processes appear hypoechoic (likely due to dorsal shadowing effect) and extend superficially, whereas the transverse processes are hyperechoic masses or lines at the lateral edge of each vertebra. In the longitudinal scan, the lateral edges of the transverse processes can be identified at the most lateral point near multiple hyperechoic nodules (Tsui & Suresh, 2010a). In this view the plexus lies between and just deep to the lateral tips of the processes.

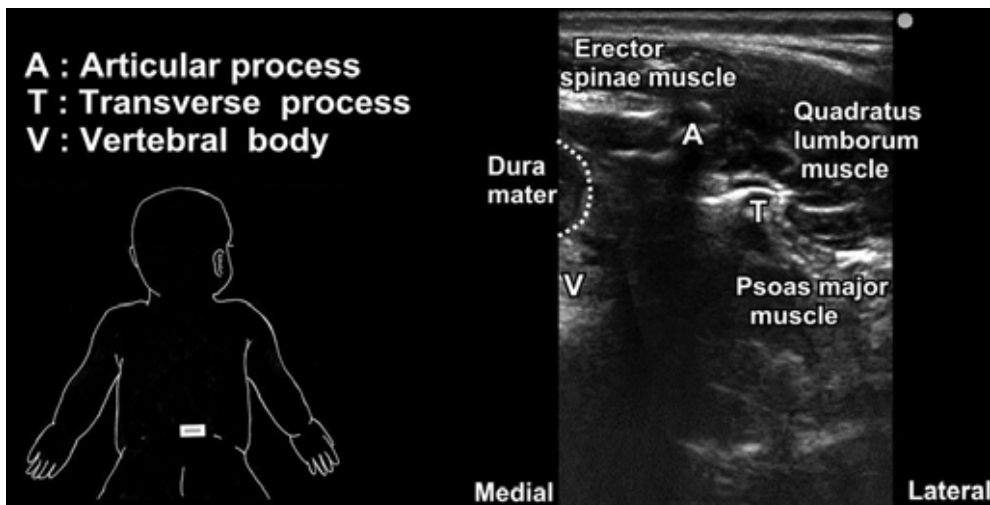


Fig. 5. Sonoanatomy at the lumbar plexus block location using a linear probe (HFL38, 6-13 MHz, 38-mm footprint) placed transversely at L4/ 5.

2.2.1.2 Technique

With the patient in the lateral decubitus position, ultrasound guidance may be used to identify the transverse processes of L4 or L5 and visualize the psoas major muscle and the plexus in relation to the paravertebral musculature. To locate the bony landmarks, it is important to alternate between transverse and longitudinal planes to survey the region of between the processes. Because of the depth and the similar echogenicity of the plexus to psoas major, however, ultrasound visualization of the nerves may not be possible in older children. In these patients, instead of real-time guidance the block is usually ultrasound

aided, meaning that location and depth of the transverse processes are determined using ultrasound but the actual needle placement is not imaged. In younger children the plexus is easier to identify because the muscle tissue appears relatively more hypoechoic than the nerve structures, which contain hyperechoic connective tissue layers (Kirchmair et al., 2004). It is best to insert the needle in a cephalad or caudad direction rather than medially towards the spinal canal.

2.2.1.3 Outcome and discussion

Visualization of the lumbar paravertebral region using sonographic imaging has been described in the literature, with the authors reporting successful intra and postoperative analgesia (Jöhr, 2005). Although ultrasound may enable visualization of the transverse processes or the plexus itself, use of a nerve stimulator, maintaining a needle puncture relatively lateral and cranial (Schuepfer & Jöhr, 2005), and performing a regular aspiration during injection are recommended to increase safety of the block. Without clear tracking of the needle tip and it may be difficult to achieve an adequate view of the local anesthetic spread, especially if the needle is inserted in a relatively medial and caudal location (Tsui & Suresh, 2010a). Therefore, a risk-benefit analysis is necessary before performing this block.

There is a lack of data in the pediatric literature describing the use of ultrasound imaging for other blocks of the nerves of the lumbar plexus, notably the fascia iliaca block, 3-in-1 block, or individual blocks of the lateral femoral cutaneous or obturator nerves. However, these blocks could all benefit from the advantages offered by ultrasound guidance. In particular, visualization of local anesthetic spread will likely reduce reliance on injecting larger than necessary volumes of local anesthetic in an attempt to block all of the related nerves (Simion & Suresh, 2007).

2.2.2 Femoral nerve block

2.2.2.1 Sonoanatomy

The femoral nerve originates from nerve roots L2, L3, and L4 and when blocked provides surgical anesthesia and analgesia for the anterior thigh extending to the knee. The femoral artery is easily visualized and serves as the principle ultrasound landmark (Figure 6). With the probe placed perpendicular to the nerve axis (*i.e.*, coronal oblique) at the level of and parallel to the inguinal crease, the nerve appears lateral to the large, circular, and anechoic femoral artery. Color Doppler may be helpful to identify the femoral vasculature. The nerve typically assumes a triangular shape but may be of variable size. The fascia lata (most superficial) and iliaca (separating the nerve from the artery) are visible superficial to the femoral nerve and most often appear as bright and longitudinally angled echogenic signals (Tsui & Suresh, 2010a).

2.2.2.2 Technique

A femoral nerve block may be used for surgical procedures on the anterior thigh and knee, including anterior thigh biopsy and knee arthroscopy. With the patient supine, the femoral artery, vein, and nerve can all be visualized with a linear probe placed along the inguinal-femoral crease. When inserted using an in-plane approach, the needle tip can be visualized as it enters the fascia iliaca. It is important that the needle be placed inside the fascia iliaca compartment. In a study comparing ultrasound guidance to nerve stimulator technique, the nerve was visible in all children studied when the probe was placed parallel and inferior to the inguinal ligament and lateral to the femoral artery. Ultrasound was also used effectively to visualize the needle tip and facilitate needle redirections (Oberndorger et al., 2007).

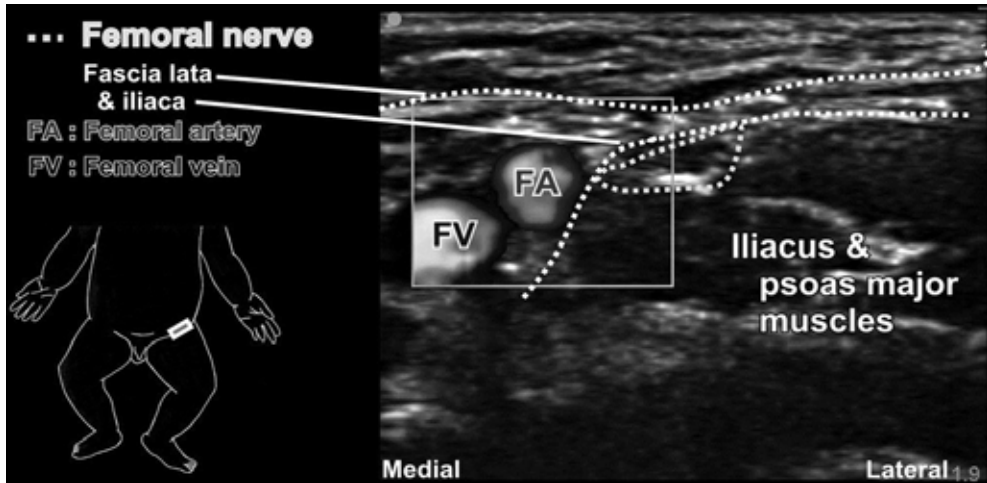


Fig. 6. Sonoanatomy at the femoral nerve block location using a linear hockey stick probe (SLA, 6-36 MHz, 25-mm footprint) placed parallel and inferior to the inguinal ligament.

2.2.2.3 Outcome and discussion

The proximity of the femoral nerve to major vasculature increases the potential for inadvertent vessel puncture and hematoma formation. Although there is no direct evidence to prove that ultrasound could reduce this risk, it is the authors' experience that fewer adverse events occurred when this block was performed under ultrasound guidance. In addition, precise ultrasound imaging of the local anesthetic spread may reduce the need for larger volumes used when injecting blindly.

2.2.3 Sciatic nerve block

2.2.3.1 Sonoanatomy

The sciatic nerve is formed by nerve roots L4 to S3 and innervates the posterior thigh and leg below the knee, with the exception of the medial portion. As it leaves the pelvis through the greater sciatic foramen, the sciatic nerve can be found inferior to the gluteus maximus muscle. The nerve lies between the ischial tuberosity and the greater trochanter, however typically only the greater trochanter can be seen when using a small foot print linear probe (Figure 7). Curved probes (curvilinear) with moderate-low frequency (*e.g.* 2-5MHz) allow deeper ultrasound beam penetration and are often necessary in older children. Although the greater trochanter and ischial tuberosity serve as the principle bony landmarks for the subgluteal approach, they must be palpated with great care as these structures do not reach adult morphology until puberty (Scheuer et al., 2000). Thus, since the size of the greater trochanter is dependent on the age of the child, it is only highly recognizable at 6 to 8 years of age (Scheuer, 2000). While the medial aspect of the greater trochanter appears largely hypoechoic, the sciatic nerve is predominantly hyperechoic and is typically elliptical in a short-axis view.

The pathway of the sciatic nerve continues through the posterior popliteal fossa before bifurcating to form the common peroneal and tibial nerves. A linear probe transversely oriented in the popliteal crease captures both the tibial and common peroneal nerves located

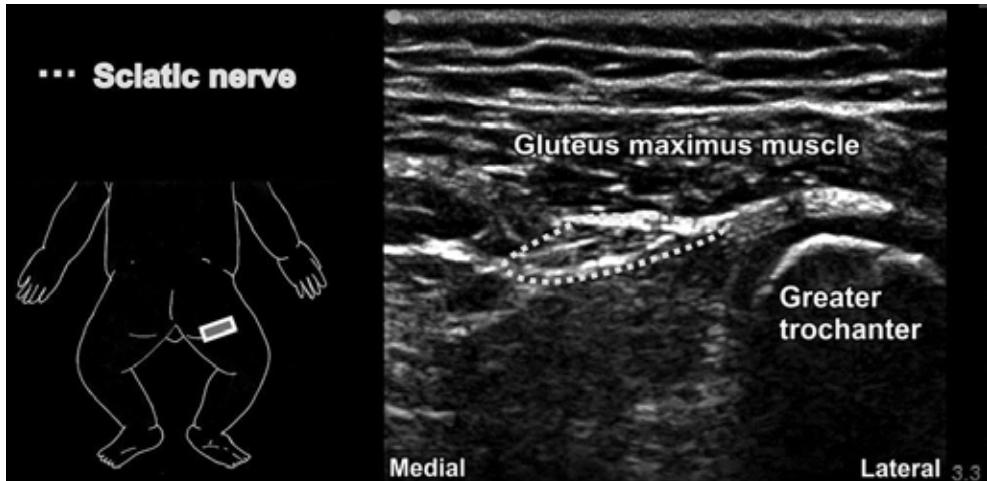


Fig. 7. Sonoanatomy at the subgluteal location using a linear probe (HFL38, 6-13 MHz, 38mm footprint). Image shows where the sciatic nerve lies at the midpoint between the ischial tuberosity and the greater trochanter of the femur.

medially and laterally, respectively, to the popliteal vessels (Figure 8). This vasculature, particularly the popliteal artery, serves as useful ultrasound landmarks (color Doppler may be useful). At the popliteal crease, the tibial nerve is found more superficial and most adjacent to the artery. However, as the probe is moved cephalad, the artery becomes deeper and more distant as the tibial nerve moves laterally to join the common peroneal nerve. At and cephalad to the bifurcation, the sciatic nerve appears as a large round to flat-oval hyperechoic structure. The biceps femoris muscle lies superficial to the bifurcating nerves and appears as a large oval shaped structure with less internal punctuate areas (hyperechoic spots) than the nerves.

2.2.3.2 Technique

A sciatic block is commonly used for surgical procedures of the foot and ankle, as well as in combination with a femoral nerve block for patients undergoing knee surgery (De Jose Maria et al., 2008). In children, subgluteal and popliteal approaches are most commonly employed. For the subgluteal approach, the child should be in the Sim's position with the hip and knee flexed (van Geffen & Gielen, 2006). To visualize the sciatic nerve in cross section, the probe should be oriented transversely at the mid point of the ischial tuberosity and the greater trochanter. The nerve can be seen deep to and at the junction where the gluteus maximus muscle meets the biceps femoris-semitendinosus muscle complex. Both in- and out-of-plane approaches have been described with success.

For a more distal block of the sciatic nerve at the popliteal fossa, it is best to place the patient in the prone position with the probe above the popliteal crease. The probe is moved cephalad until the nerves merge together. Using an in-plane approach, the needle is placed in close proximity to the sciatic nerve and the local anesthetic spread surrounds the nerve.

To achieve an ideal image, a probe appropriate to the size of the child must be used. Deeper structures in older children require lower frequency probes for sufficient visualization. Such a low frequency probe might be necessary for the subgluteal approach as there is

considerable variation in the depth of the sciatic nerve in older children. In contrast, high-frequency linear probes are more advantageous for popliteal blocks.

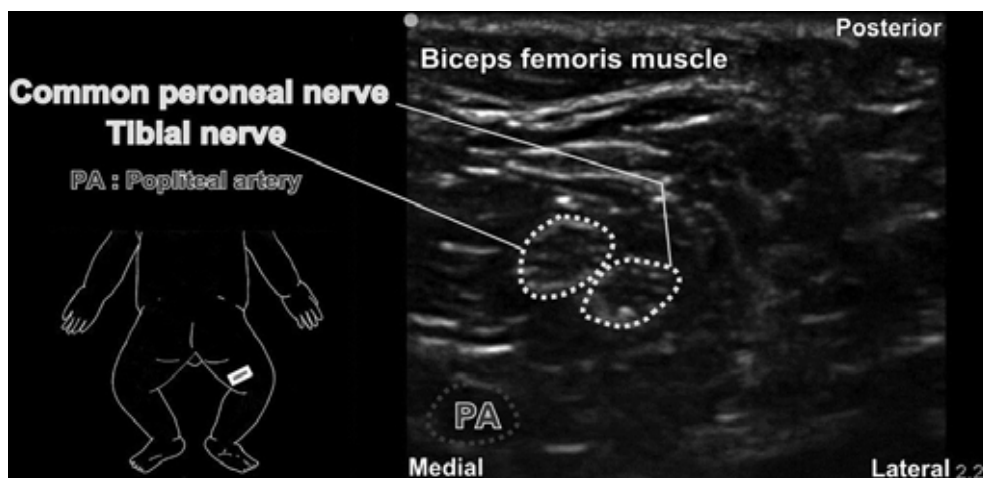


Fig. 8. Sonoanatomy in the popliteal fossa just distal to bifurcation of the sciatic nerve using a linear hockey stick probe (SLA, 6-13, 25-mm footprint).

2.2.3.3 Outcome and discussion

Ultrasound imaging can be particularly beneficial when using blind catheter insertion to confirm the spread of local anesthetic around the nerve. In addition, ultrasound guidance can be advantageous in instances in which a blind technique is likely to fail. An example of this was described for patients with venous malformations. The use of ultrasound in these patients helped the anesthesiologist avoid vascular puncture during needle placement (van Geffen et al., 2007). Due to the high degree of variability in the division of the sciatic nerve, ultrasound also offers considerable advantages in nerve localization when using the popliteal approach (Schwemmer et al., 2004).

2.3 Truncal blocks

Truncal blocks are becoming a more popular means of providing analgesia for procedures in the umbilical or epigastric regions. The ability to visualize relevant musculature and fascial layers with ultrasound offers an advantage over the more subjective conventional technique of detecting “pops” or “clicks” upon penetration into fascial compartments. This is particularly beneficial in children due to the close proximity of nerve and critical abdominal structures. In addition, visualization of the local anesthetic spread made possible with ultrasonography has the potential to improve success rates and allow for administration of minimal volumes of local anesthetic (Willschke et al., 2005, Willschke et al., 2006).

2.3.1 Ilioinguinal-iliohypogastric block

2.3.1.1 Sonoanatomy

The ilioinguinal and iliohypogastric nerves supply the groin area and are derived from the L1 nerve root of the thoracolumbar plexus. Both nerves are seen as hypoechoic structures

between the internal oblique and transversus abdominis muscles. A short-axis view of the ilioinguinal nerve running in the transversus abdominis plane (TAP) can be viewed using a probe placed medial to the superior aspect of the anterior superior iliac spine (ASIS) (Figure 9). The ASIS appears nodular in shape and hypoechoic due to the dorsal shadowing beyond the highly reflective periosteum. The lateral abdominal muscles appear with numerous hyperechoic dots within a hypoechoic background (a “starry night” appearance). Any hyperechoic divisions between the muscles represent fascial compartments.

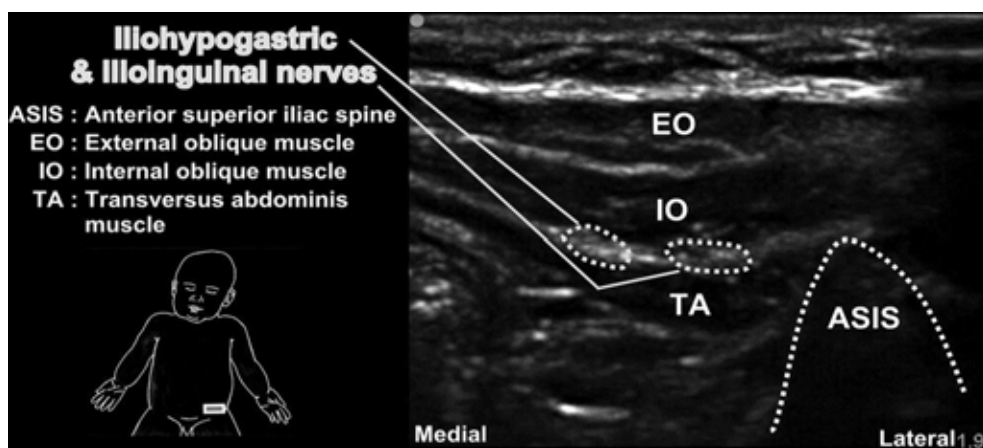


Fig. 9. Sonoanatomy of the ilioinguinal-iliohypogastric nerve block location medial to the ASIS using a linear hockey stick probe (SLA, 6-13 MHz, 25-mm footprint).

2.3.1.2 Technique

This block is commonly used for patients undergoing surgery involving the inguinal region, including hernia repair, orchiopexy, or groin surgery. When performed successfully, these blocks can be as effective as caudal blocks and may be used when a caudal block is contraindicated (Markham et al., 1986). When using a linear probe, it should be placed at the highest point of the iliac crest with the axis facing the umbilicus. This orientation provides a clear view of the relevant muscle layers and nerves as they run in the TAP. Using an in-plane approach, a needle is inserted toward the ilioinguinal and iliohypogastric nerves. After a small test injection of dextrose (1-2ml) to confirm the spread between the muscles and close to the nerves, local anesthetic can be injected into the space.

2.3.1.3 Outcome and discussion

The use of conventional techniques for the ilioinguinal nerve block based on the observance of clicks to determine penetration of the abdominal muscles as a reported success rate of approximately 70% (Lim et al., 2002). Part of the block failure may be attributed to inaccurate nerve localization using traditional landmark-based needle insertion sites and the fascial click method to determine injection. A study by Wientraud et al, used ultrasonography to determine the actual location of local anesthetic distribution when it was injected using traditional methods. The local anesthetic surrounded the nerves in only 14% of blocks (Wientraud et al, 2008). Thus, the use of ultrasound guidance to visualize the plane of nerve localization, needle trajectory, and local anesthetic dispersion offers significant opportunity for improvement.

Pharmacodynamic studies have demonstrated the efficacy of lower doses of local anesthetics for managing postoperative pain in children who received these blocks under ultrasound guidance. The authors also believe using lower volumes could reduce the risk of local anesthetic toxicity (Willschke et al., 2006). The use of lower volumes of local anesthetic is also supported by a recent pharmacokinetic study that found higher plasma levels of ropivacaine using ultrasound guidance when compared to a single pop technique (Weintraud et al., 2009).

2.3.2 Transversus Abdominis Plane (TAP) block

2.3.2.1 Sonoanatomy

The TAP is a potential space located between the internal oblique and the transversus abdominis muscles. The thoracolumbar nerve roots, T8-L1, run in the TAP. The 3 muscle layers: external oblique, internal oblique, and transversus abdominis, serve as easily identified landmarks in an ultrasound image (Figure 10). However, there may not be a clear distinction between the individual muscles. The external oblique is most superficial and lies above the internal oblique, followed by the transversus abdominis. Deep to the muscles, the peritoneum appears as a hypoechoic region. The nerves for this block have similar echogenicity when compared to the muscles and travel tangentially to the ultrasound beam axis. As a result, the nerves will not be visualized.

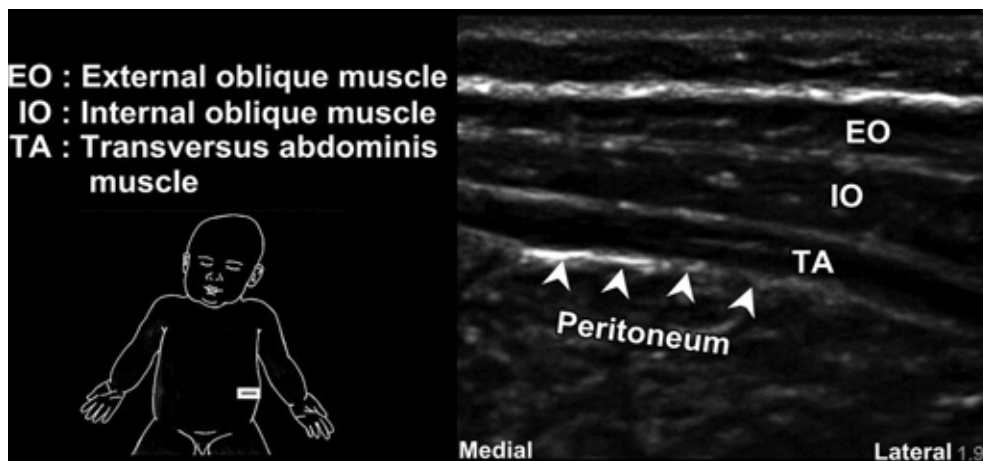


Fig. 10. Sonoanatomy at the TAP using a linear hockey stick probe (SLA, 6-13 MHz, 25-mm footprint).

2.3.2.2 Technique

TAP blocks may be used to provide analgesia for a variety of abdominal procedures as well as chronic neuropathic abdominal wall pain (McDonnell et al., 2007). This block is particularly useful when a central neuraxial blockade is contraindicated. Performing a TAP block in pediatric patients under ultrasound guidance has been described using a step-by-step approach (Pak et al., 2009). A high-frequency linear probe or hockey stick probe is placed on the abdomen lateral to the umbilicus. The probe can be shifted laterally to identify the three layers of the abdominal wall. Next, a needle is placed at or slightly posterior to the

midaxillary line using an in-plane approach. The needle should be inserted into the plane between the internal oblique and the transversus abdominis muscles and the local anesthetic is injected into this potential space. The local anesthetic dispersion will appear as an elliptical opening of the potential space. If this spread is not observed, it is important to hydrodissect with small injections of local anesthetic solution or saline until the exact plane of injection is recognized.

2.3.2.3 Outcome and discussion

In adults, the anesthesiologist may rely on palpating the lumbar triangle of Petit to find the internal oblique muscle that lies at its base (Rafi, 2001). However, this triangle is not easily palpable in children, making ultrasound a valuable tool for determining needle placement. Because it includes blockade of the first lumbar nerve root, a TAP block may be used instead of an ilioinguinal/ iliohypogastric block when images from the region anterior and medial to the ASIS are not ideal (Fredrickson et al., 2008).

3. Neuraxial blocks

Performing central neuraxial blocks in pediatric patients can be challenging, due in part to the narrow safety margin for needle placement in the spinal canal and tight positioning of anatomical structures. While the use of ultrasound in neuraxial anesthesia in adults is somewhat limited because of poor beam penetration through the ossified bony vertebral column, it could be of much greater value in pediatric patients. In contrast to adults, children have limited ossification, thus allowing good visual resolution of the anatomy and block-related equipment or solutions (Tsui & Suresh, 2010b). Despite an increasing amount of literature supporting the use of ultrasound guided neuraxial blocks, the benefit of ultrasound has not yet been established for block performance or outcome in all patients.

3.1 Epidural Analgesia

3.1.1 Sonoanatomy

Visualization is typically easier in younger children because of the largely cartilaginous composition of their vertebral columns. To capture an overview of neuraxial structures, the probe should be placed both in transverse and longitudinal planes. In a transverse view, the central vertebral body in the region of L3/ L4 appears as a hyperechoic “V” in contrast to the more hypoechoic paravertebral muscles. Bony structures such as the spinous processes are useful in identifying the midline (Figure 11). The *ligamentum flavum* and *dura mater* may be visualized as hyperechoic lines in the transverse view, although the *dura mater* becomes more difficult to see in children older than 6 months (Tsui & Suresh, 2010b). Deep to the *dura*, fibers of the cauda equina appear as hyperechoic dots in an anechoic space filled with cerebrospinal fluid.

Using a paramedial longitudinal view at the level of the thoracic vertebrae, the spinous processes and laminae are easy to identify as slanted hyperechoic lines. Deep to the *ligamentum flavum* and *dura mater*, the spinal cord appears as a hypoechoic structure with two distinguishing features: a central line of hyperechogenicity representing the median sulcus, and a bright outer covering of the pia mater (Figure 12).

3.1.2 Technique

A report by Rapp *et al.* examined the use of ultrasound preoperatively to visualize the sacral, lumbar, and thoracic regions (Rapp et al., 2005). The authors used ultrasound to measure the

skin to *ligamentum flavum* distance to determine the depth of loss of resistance. An assistant is recommended during catheter placement if real time imaging is desired. In this study a separate individual positioned the probe in the paramedial longitudinal plane at the level of insertion while the anesthesiologist performed the epidural puncture. Ultrasound images were used to monitor the loss of resistance, seen as a ventral displacement of the *dura mater* and widening of the epidural space.

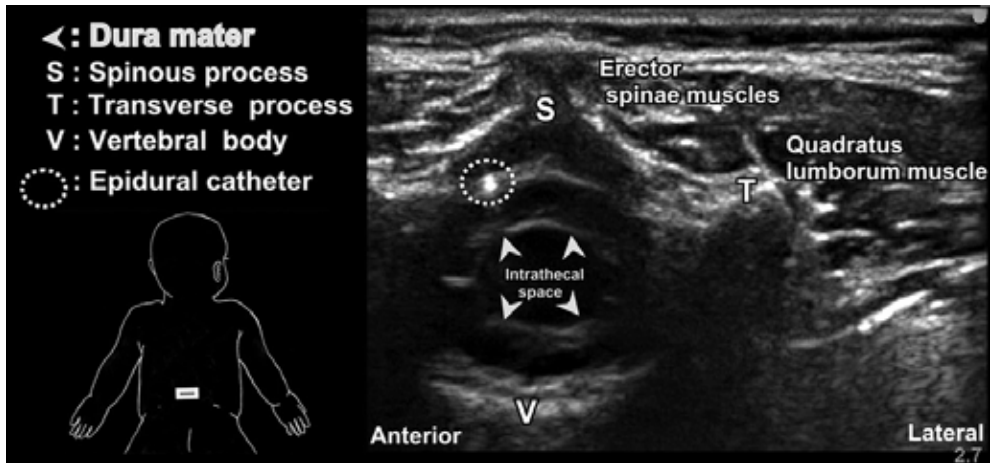


Fig. 11. Sonoanatomy of the spinal column and canal in a transverse axis at the L3/ L4 level using a linear probe (HFL38, 6-13 MHz, 38 mm footprint).

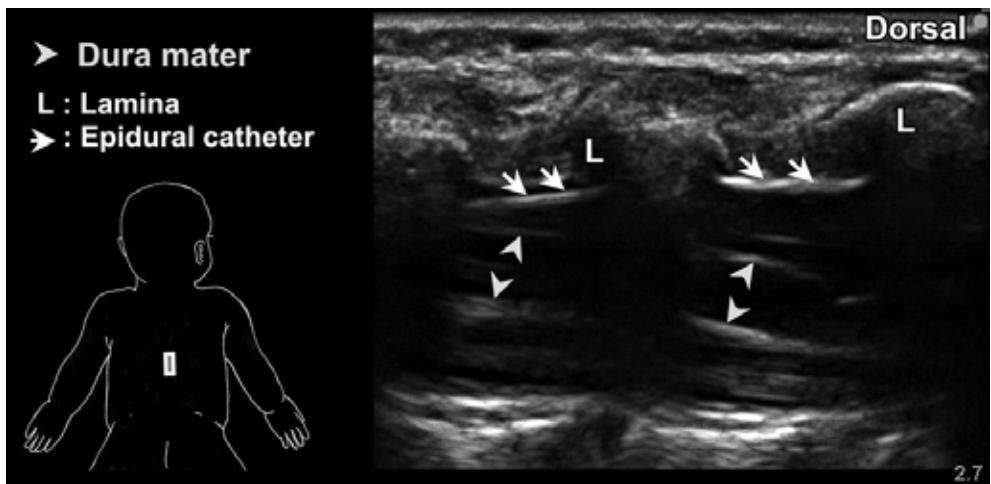

Fig. 12. Sonoanatomy of the spinal column and canal in a paramedian longitudinal view at the midthoracic level using a linear probe (HFL38, 6-13 MHz, 38 mm footprint).

A randomized controlled trial by Willschke et al. also studied the use of ultrasound guidance for determining loss of resistance (Willschke et al., 2006). The procedure was

performed with the child in the lateral position with knees flexed. Similar to the technique described by Rapp et al, an assistant operated the probe in a paramedial longitudinal plane while the anesthesiologist performed a midline puncture. The needle was inserted after visualization of the *dura mater* and the needle was followed on its course through the *ligamentum flavum* into the epidural space. Ultrasound imaging was also used to confirm the tip of the catheter and local anesthetic spread.

3.1.3 Outcome and discussion

Ultrasound imaging for epidural analgesia may be beneficial either preprocedurally (before puncture) or during (in real time) block performance to estimate the depth to the epidural space as well as the spread of the local anesthetic. When identifying the epidural space, studies have found that the *dura mater* is typically more clearly visible than the *ligamentum flavum* (Marhofer et al., 2005; Kil et al., 2007). The benefits of preprocedural ultrasound may be more substantial in obese children in whom the landmarks are difficult to palpate (Kawaguchi et al., 2007). A randomized study compared ultrasound guidance with loss of resistance technique for the placement of both lumbar and thoracic level epidural catheters (Willschke et al., 2006). Although the authors found ultrasound guidance to be superior in terms of the number of bone contacts and speed of execution, at this time ultrasound guidance does not obviate continuous testing for loss of resistance.

There is also evidence to suggest that ultrasound may enable visualization of static structures like catheters (Chawathe et al., 2003). This is possible by one of two methods: monitoring the movement of the local anesthetic as the catheter moves through the solution, or noting the ventral movement of the *dura mater*.

3.2 Caudal block

3.1.1 Sonoanatomy

Preprocedural imaging in both the transverse and longitudinal planes is important to identify the sacrococcygeal ligament, dural sac, and cauda equina. With the probe placed in the transverse plane at the level of the coccyx, the sacral hiatus is visible between two hyperechoic lines: the superior line represents the sacrococcygeal ligament while the inferior represents the dorsum of the pelvic surface of the sacrum (Figure 13). When the probe is placed in a longitudinal plane between the sacral cornua, the dorsal surface of the sacrum, dorsal aspect of the pelvic surface of the sacrum, as well as the sacrococcygeal ligament are viewed. The ligament can be identified as a thick, linear, hyperechoic band that slopes caudally. When ossification has occurred at the midline, as is the case in older children, the paramedial longitudinal view is optimal because it allows the ultrasound beam to penetrate the spaces lateral to the spinous processes (Roberts & Galvez, 2005).

3.2.2 Technique

Current research supports the use of ultrasound imaging in both the transverse (Raghunathan et al., 2008; Schwartz et al., 2008) and longitudinal (Roberts & Galvez, 2005; Park et al., 2006) planes to guide needle placement during a caudal block. For the transverse technique, the probe was placed just cephalad to the point of injection. Ultrasound imaging allowed visualization of local anesthetic injection within the caudal epidural space, made evident by the presence of localized turbulence and a swelling of the caudal space (Schwartz et al., 2008).

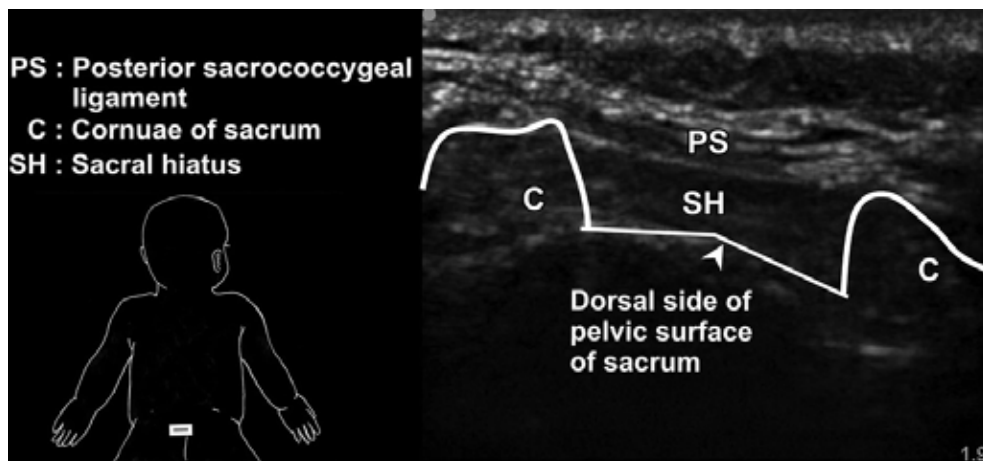


Fig. 13. Sonoanatomy of the caudal epidural space at the level of the sacral hiatus using a linear hockey stick probe (SLA, 6-13 MHz, 25 mm footprint) placed in the transverse plane.

The longitudinal technique allows a long axis view of the needle as it penetrates the sacrococcygeal ligament and thus is particularly valuable in determining accurate angle and depth of the needle. Park et al. used ultrasound in children age 2-84 months to determine the optimal angle of needle entry (Park et al., 2006). The authors found a needle angle of 21 degrees to the skin surface to be successful in 92.3% of patients studied. A similar technique has been found to be successful for catheter insertion into the caudal space. The position of the catheter is possible with ultrasound imaging (Roberts & Galvez, 2005).

3.2.3 Outcome and discussion

Caudal blocks for lower extremity and perineal perioperative analgesia are one of the most commonly practiced regional anesthesia techniques in children. However, they can be associated with higher rates of complications than peripheral blocks, notably bloody punctures and intravascular injections (Giaufre et al., 1996; Lacroix, 2008). To reduce these risks, it is important to have correct needle placement when performing the block. The use of epidural electrical stimulation may be used in conjunction with ultrasound guidance to ensure proper needle placement within the caudal epidural space. When compared to the swoosh test for confirming caudal epidural placement, investigators found real time ultrasonography to have significantly higher sensitivity and negative predictive value (Raghunathan et al., 2008). The low negative predictive value may be explained in part by the older age of the patients (5-8 yrs).

Similar to that described in the adult literature, it may be beneficial to use both transverse and longitudinal planes; the longitudinal plane to view the needle puncture followed by a transverse plane to ensure local anesthetic dispersion (Chen et al., 2004). Although there is an increasing amount of literature illustrating the advantages of clearer visualization of anatomical structures as well as the needle, more evidence is needed to clearly define the benefits of ultrasound imaging in neuraxial blocks. For the caudal block in particular, ultrasound guidance may be considered cumbersome for the standard patient, however it may be a useful tool in obese patients in whom poorly palpable landmarks make the blind approach more difficult.

Block	Indications	Ultrasound Landmark
Axillary	Surgery of the elbow, forearm, or hand	Axillary artery
Interscalene	Surgery of the shoulder or proximal arm, catheter placement for postoperative pain control	Scalene muscles and subclavian artery
Supraclavicular	Most surgical procedures of the upper extremity distal to the midhumerus	Subclavian artery
Infraclavicular	Surgery of the arm and elbow, catheter placement for major reconstructive procedures	Subclavian artery and vein
Lumbar plexus	Surgery of the hip or knee	Transverse processes
Femoral nerve	Surgical procedures of the anterior knee and thigh	Femoral artery
Sciatic nerve	Most surgical procedures of the foot and ankle, may be used in conjunction with a femoral block for knee surgery	Subgluteal: greater trochanter and ischial tuberosity Popliteal: popliteal artery
Ilioinguinal-iliohypogastric	Hernia repair or groin surgery	Two to three muscle layers (external oblique and aponeurosis) and the anterior superior iliac spine
Transversus abdominis plane	Major abdominal procedures, chronic neuropathic abdominal wall pain	Three muscle layers: external oblique, internal oblique, transversus abdominis
Epidural analgesia (lumbar)	Surgery of the lower extremity or abdomen	<i>Ligamentum flavum</i> , <i>dura mater</i> , and bony structures (midline spinous processes in transverse plane, laminae in paramedial longitudinal plane)
Caudal	Perineal surgery	Dorsum of pelvic surface of the sacrum and hyperechoic sacrococcygeal membranes on the two coruna

Table 1. Common peripheral and neuraxial nerve blocks in children

3.3 Spinal anesthesia

Although ultrasound imaging has the potential to facilitate needle guidance and determination of the depth of the subarachnoid space, to the authors' knowledge there is no published literature available at this time that has studied this aspect of pediatric spinal anesthesia.

4. References

- Bernards, CM.; Hadzic, A.; Suresh, S. & Neal, JM. (2008). Regional anesthesia in anesthetized or heavily sedated patients. *Reg Anesth Pain Med*, Vol. 33, 189-93
- Chawathe, MS.; Jones, RM. ; Gildersieve, CD. ; Harrison, SK. ; Morris, SJ & Eickmann, C. (2003). Detection of epidural catheters with ultrasound in children. *Pediatr Anesth*, Vol. 13, 681-4
- Chen, CP. ; Tang, SF. ; Hsu, TC. ; Tsai, WC. ; Liu, HP. ; Chen, MJ Date, E. & Lew, HL. (2004). Ultrasound guidance in caudal epidural needle placement. *Anesthesiology*, Vol. 101, 181-4
- Chin, KJ ; Chan VW. & van Geffen, GJ (2008). Ultrasound-guided infraclavicular block : The in-plane versus out-of-plane approach. *Paediatr Anaesth*, Vol. 18, 1279-80
- Cregg, N. ; Conway, F. & Casey, W. (1996). Analgesia after otoplasty : regional nerve blockade vs local anaesthetic infiltration of the ear. *Can JAnesth*, Vol. 43, No. 2, 141-7
- De Jose Maria, B. & Tielens, LK. (2004). Vertical infraclavicular brachial plexus block in children : A preliminary study. *Paediatr Anaesth*, Vol. 14, 931-5
- De Jose Maria, B. ; Banus, E. ; Navarro, EM. ; Serrano, S. ; Perello, M. & Marbok, M. (2008). Ultrasound-guided supraclavicular vs infraclavicular brachial plexus blocks in children. *Pediatr Anesth*, Vol. 18, 838-44
- Fleischmann, E. ; Marhofer, P. ; Greher, M. ; Walzl, B. ; Sitzwohl, C. & Kapral, S. (2003). Brachial plexus anesthesia in children : lateral infraclavicular vs axillary approach. *Pediatr Anaesth*, Vol. 13, No. 2, 103-8
- Fredrickson, MJ (2007). Ultrasound-assisted interscalene catheter placement in a child. *Anesth Intensive Care*, Vol. 35, 807-8
- Fredrickson, M. ; Seal, P. & Houghton, J (2008). Early experience with the transversus abdominis plane block in children. *Paediatr Anaesth*, Vol. 18, 891-2
- Giaufre, E. ; Dalens, B. & Gombert, A. (1996). Epidemiology and morbidity of regional anesthesia in children : A one year prospective Survey of the French-Language Society of Pediatric Anesthesiologists. *Anesth Analg*, Vol. 83, 904-12
- Greher, M. ; Retzl, G. ; Niel, P. ; Kamolz, L. ; Marhofer, P. & Kapral, S. (2002). Ultrasonographic assessment of topographic anatomy in volunteers suggests a modification of the infraclavicular vertical brachial plexus block. *Br JAnaesth*, Vol. 88, 632-6
- Johr, M. (2005). The right thing in the right place : Lumbar plexus block in children. *Anesthesiology*, Vol. 101, 445-50
- Kawaguchi, R. ; Yamauch, M. ; Sugino, S. ; Tsukigase, N. ; Omote, K. & Namiki, A. (2007). Two cases of epidural anesthesia using ultrasound Imaging. *Masui*, Vol. 56, 702-5

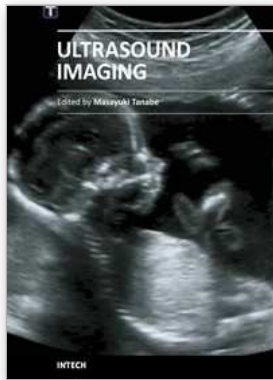
- Kil, HK ; Cho, JE ; Kim, WO. ; Koo, BN. ; Han, SW. & Kim, JY. (2007). Prepuncture ultrasound-measured distance : An accurate reflection of epidural depth in infants and small children. *Reg Anesth Pain Med*, Vol. 32, 102-6
- Kirchmair, L. ; Enna, B. ; Mitterschiffthaler, G. ; Moriggl, B. ; Greher, M. ; Marhofer, P. ; Kapral, S. & Grassner, I. (2004). Lumbar plexus in children. A sonographic study and its relevance to pediatric regional anesthesia. *Anesthesiology*, Vol. 101, 445-50
- Lacroix, F. (2008). Epidemiology and morbidity of regional anesthesia in children. *Curr Opin Anesthesiol*, Vol. 21, 345-9
- Lim, SL ; Ng, SA. & Tan, GM. (2002). Ilioinguinal and iliohypogastric nerve block revisited : Single shot versus double shot technique for hernia repair in children. *Paediatr Anesth*, Vol 12, 255-60
- McDonnell, JG. ; O'Donnell, B. ; Curley, G. ; Heffernan, A. ; Power, C. & Laffey, JG. (2007). The analgesic efficacy of transversus abdominis plane block after abdominal surgery : a prospective randomized controlled trial. *Anesth Analg*, Vol. 104, 193-197
- Marhofer, P. ; Bosenber, A. ; Sitzwohl, C. ; Willschke, H. ; Wanzel, O. & Kapral, S. (2005). Pilot study of neuraxial Imaging by ultrasound in infants and children. *Pediatr Anesth*, Vol. 32, 102-6
- Marhofer, P. ; Greher, M. & Kapral, S. (2005). Ultrasound guidance in regional anaesthesia. *Br J Anaesth*, Vol. 94, No. 1, 7-17
- Marhofer, P. ; Sitzwohl, C. ; Greher, M. & Kapral, S. (2004). Ultrasound guidance for infraclavicular brachial plexus anaesthesia in children. *Anesthesia*, Vol. 59, 642-6
- Markham, SI ; Tomlinson, J & Hain, WR. (1986). A comparison with caudal block for intra and postoperative analgesia. *Anesthesia*, Vol. 41, 1098-103
- Oberndorfer, U. ; Marhofer, P. ; Bosenberg, A. ; Wilschke, H. ; Felfernig, M. ; Weintraud, M. ; Kapral, S. & Kettner, SC. (2007). Ultrasonographic guidance for sciatic and femoral nerve blocks in children. *Br J Anaesth*, Vol. 98, 797-801
- Park, JH. ; Koo, BN. ; Kim, JY. ; Cho, JE. ; Kim, WO. & Kil, HK. (2006). Determination of the optimal angle for needle insertion during caudal block in children using ultrasound Imaging. *Anesthesia*, Vol. 61, 946-9
- Pak, T. ; Mickelson, J ; Yerkes, E. & Suresh, S. (2009). Transverse abdominis plane block : a new approach to the management of secondary hyperalgesia following major abdominal surgery. *Paediatr Anaesth*, Vol. 19, No. 1, 54-56
- Rafi, AN. (2001). Abdominal field block : A new approach via the lumbar triangle. *Anesthesia*, Vol. 56, 1024-6
- Raghunathan, K. ; Schwartz, D. & Connelly, NR. (2008). Determining the accuracy of caudal needle placement in children: A comparison of the swoosh test and ultrasonography. *Pediatr Anesth*, Vol. 18, 606-12
- Rapp, HJ ; Folger, A. & Grau, T. (2005). Ultrasound-guided epidural catheter insertion in children. *Anesth Analg*, Vol. 101, 333-9
- Rapp, H. & Grau, T. (2004). Ultrasound-guided regional anesthesia in pediatric patients. *Techn Reg Anesth Pain Manag*, Vol. 8, 179-98
- Roberts, SA. & Galvez, I. (2005). Ultrasound assessment of caudal catheter position in infants. *Pediatr Anesth*, Vol. 15, 429-32

- Scheuer, L. (2000). The lower extremity, in Scheuer, L. (ed), *Developmental Juvenile Osteology*, Academic Press, London, pp. 374-467
- Scheuer, L. ; Black, S. & Christie, A. (2000). The pelvic girdle in Scheuer, L. (ed.), *Developmental Juvenile Osteology*, Academic Press, London, pp. 342-73
- Schuepfer, G. & Jhr, M. (2005). Psoas compartment block in children : Part I- Description of the technique. *Paediatr Anaesth*, Vol. 15, 461-4
- Schwartz, D. ; Raghunanathan, K. ; Dunn, S. & Connelly, NR. (2008). Ultrasonography and pediatric caudals. *Anesth Analg*, Vol. 106, 97-9
- Simion, C. & Suresh, S. (2007). Lower extremity peripheral nerve blocks in children. *Tech Reg Anesth Pain Manag*, Vol. 11, 222-8
- Suresh, S. ; Barcelona, SL. ; Young, NM. ; Seligman, I. ; Heffner, CL. & Cote, CJ (2009). Postoperative pain relief in children undergoing tympanomastoid surgery : is a regional block better than opioids ? *Anesth Analg*, Vol. 94, No. 4, 859-62
- Schwemmer, U. ; Markus, CK. ; Greim, CA. ; Brederlau, J. ; Trautner, H. & Roewer, N. (2004). Sonographic Imaging of the sciatic nerve and its division in the popliteal fossa in children. *Pediatr Anesth*, Vol. 14, 1005-8
- Tsui, BC. & Suresh, S. (2010a). Ultrasound imaging for regional anesthesia in infants, children, and adolescents : a review of current literature and its application in the practice of extremity and trunk blocks. *Anesthesiology*, Vol. 112, No. 2, 473-92
- Tsui, BC. & Suresh, S. (2010b). Ultrasound Imaging for regional anesthesia in infants, children and adolescents : A review of current literature and its application in the practice of neuraxial blockade. *Anesthesiology*, Vol. 112, 719-28
- Van Geffen, GJ & Gielen, M. (2006). Ultrasound-guided sublumbar sciatic nerve blocks with stimulating catheters in children : A descriptive study. *Anesth Analg*, Vol 103, 328-337
- Van Geffen, GJ ; McCartney, CJ ; Gielen, M. & Chan, VW. (2007). Ultrasound as the only nerve localization technique for peripheral nerve block. *J Clin Anesth*, Vol 19, 381-5
- Van Geffen, GJ ; Tielens, L. & Gielen, M. (2006). Ultrasound-guided interscalene brachial plexus block in a child with femur fibula ulna syndrome. *Pediatr Anesth*, Vol. 16, 330-2
- Weintraud, M. ; Lundblad, M. ; Kettner, SC. ; Wilschke, H. ; Kapral, S. ; Lonnqvist, PA. ; Koppatz, K. ; Turnheim, K. ; Bosenberg, A. & Marhofer, P. (2009). Ultrasound versus Landmark-based technique for ilioinguinal-iliohypogastric nerve blockade in children : The implications on plasma levels of ropivacaine. *Anesth Analg*, Vol. 108, 1488-92
- Weintraud, M. ; Marhofer, P. ; Bosenberg, A. ; Kapral, S. ; Siltschke, H. ; Felfernig, M. & Kettner, S. (2008). Ilioinguinal/ iliohypogastric blocks in children : Where do we administer the local anesthetic without direct visualization ? *Anesth Analg*, Vol. 18, 89-93
- Willschke, H. ; Bosenberg, A. ; Marhofer, P. ; Johnston, S. ; Kettner, S. ; Eichenberger, U. ; Wanzel, O. & Kapral, S. (2006). Ultrasonographic-guided ilioinguinal/ iliohypogastric nerve block in pediatric anesthesia : What is the optimal volume ? *Anesth Analg*, Vol. 102, 1680-4

- Willschke, H. ; Marhofer, P. ; Bosenberg, A. ; Johnston, S. ; Wanzel, O. ; Cox, SG. ; Sitzwohl, C. & Kapral, S. (2005). Ultrasonography for ilioinguinal/ iliohypogastric nerve blocks in children. *Br JAnaesth*, Vol. 95, 226-30
- Willschke, H. ; Marhofer, P. ; Bosenberg, A. ; Johnston, S. ; Wanzel, O. ; Sitzwohl, C. ; Kettner, S. & Kapral, S. (2006). Comparing a novel approach using ultrasound guidance and a standard loss-of-resistance technique. *Br JAnaesth*, Vol. 97, 200-7

INTECH

INTECH



Ultrasound Imaging

Edited by Mr Masayuki Tanabe

ISBN 978-953-307-239-5

Hard cover, 210 pages

Publisher InTech

Published online 11, April, 2011

Published in print edition April, 2011

In this book, we present a dozen state of the art developments for ultrasound imaging, for example, hardware implementation, transducer, beamforming, signal processing, measurement of elasticity and diagnosis. The editors would like to thank all the chapter authors, who focused on the publication of this book.

How to reference

In order to correctly reference this scholarly work, feel free to copy and paste the following:

Santhanam Suresh, Lauren J. Taylor and Amar S. Minhas (2011). Ultrasound Imaging for Pediatric Anesthesia: A Review, Ultrasound Imaging, Mr Masayuki Tanabe (Ed.), ISBN: 978-953-307-239-5, InTech, Available from: <http://www.intechopen.com/books/ultrasound-imaging/ultrasound-imaging-for-pediatric-anesthesia-a-review>

INTECH

open science | open minds

InTech Europe

University Campus STeP Ri
Slavka Krautzeka 83/A
51000 Rijeka, Croatia
Phone: +385 (51) 770 447
Fax: +385 (51) 686 166
www.intechopen.com

InTech China

Unit 405, Office Block, Hotel Equatorial Shanghai
No.65, Yan An Road (West), Shanghai, 200040, China
中国上海市延安西路65号上海国际贵都大饭店办公楼405单元
Phone: +86-21-62489820
Fax: +86-21-62489821

