6 The Operations

BASIC PRINCIPLES

Basic principles are described here; strategies for specific situations are discussed in later sections. The basic principles in the repair of a fistula are:

- adequate exposure
- protection of the ureters
- separation of the vagina from the bladder around the fistula
- mobilization of enough bladder after excision of scar to allow a tension-free closure of the defect that shows no leakage on dye test
- support for the urethra when it is deficient.

These principles are now described and illustrated.

Fistulae come in all different shapes, sizes and sites, but the basic principles of the surgical technique can be applied to all. Distal (the urethral end) and proximal are used to denote the parts of the fistula in the operative descriptions (Figure 6.1).

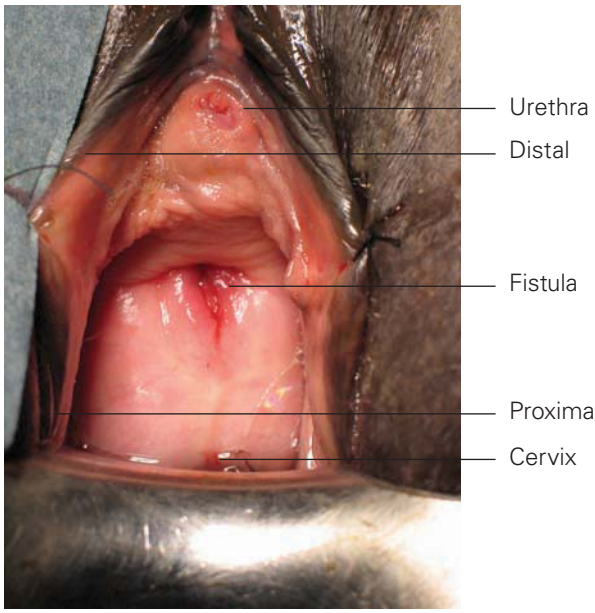

Figure 6.1 Definition of 'distal' and 'proximal'.

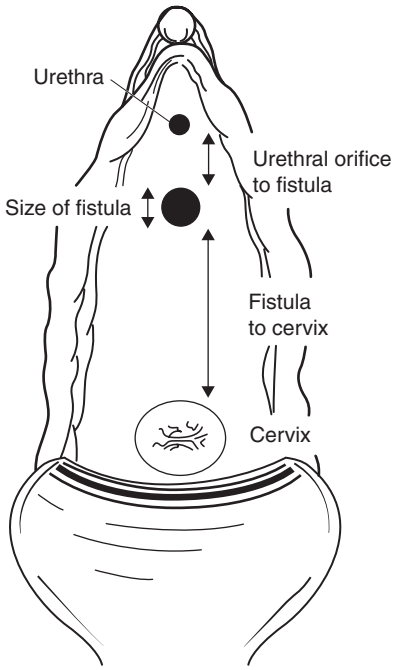

Figure 6.2 Measurements to make.

Documentation of the fistula

The fistula must be described. We use Goh's classification (see Chapter 1).

First, the vagina is assessed for depth and stenosis. The fistula is described by its site, size and surrounding scar. By palpation, an attempt should be made to determine whether the bladder has been separated from the urethra. The cervix should be inspected and palpated for damage, and the posterior wall checked for any missed rectal injury.

An attempt should be made to measure the distance from the external urethral orifice to the distal fistula margin (Figure 6.2) and to estimate the size of the bladder (Figure 6.3). (A sound or metal catheter marked in centimetres is ideal, although a practical alternative is to know the length of one's thumb's distal phalanx for estimating urethral length.)

It is vital to tap the interior of the bladder to detect stones (Figure 6.3). *To overlook a stone during a repair is a disaster.* Any stones should be recognized and removed before the repair. Although calculi occurred in only 3% of our Ugandan series, most were in fact easily detected before the patient reached theatre (see 'Bladder stones' later in this chapter).

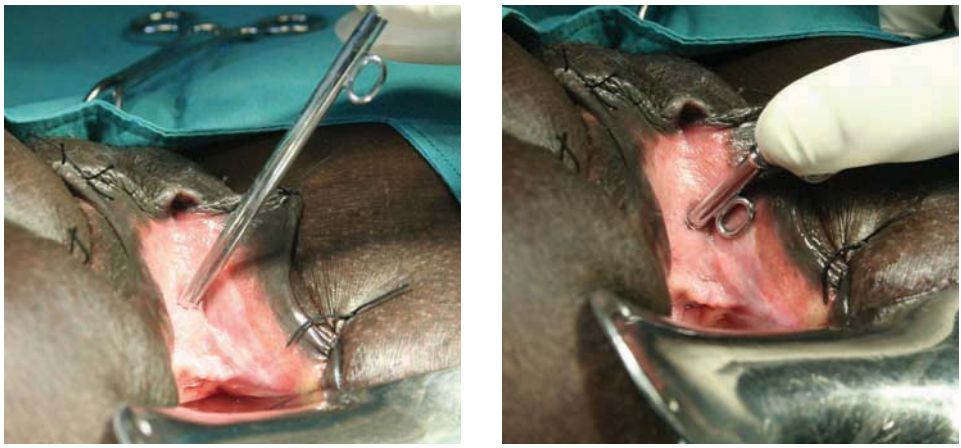

Figure 6.3 Sounding the bladder for stones and size.

Access

The labia are first sutured laterally to improve access, and a swab is sutured to cover the anus (Figure 6.4).

In more complex cases, it is common to find scarring inside the vagina that is sufficiently severe to prevent the insertion of the Auvard speculum. Most commonly, there is a thick band of scar on the posterior vaginal wall. The scar is released by incising the band laterally either side, staying away from the rectum and the bladder. If there is any doubt, a finger can be inserted into the rectum for guidance. Incising the scar in this way may result in a reasonable vaginal capacity. In cases of extensive scarring, the lateral incisions can be brought infero-laterally out into the ischio-rectal fossa, making large episiotomies. An Auvard speculum can then be introduced, exposing the fistula.

More frequently, a simple episiotomy, bilateral on occasions, will improve access greatly (Figure 6.5). Beginners will need to make episiotomies more frequently than experienced surgeons.

Figure 6.4 The labia are sutured and the anus is covered.

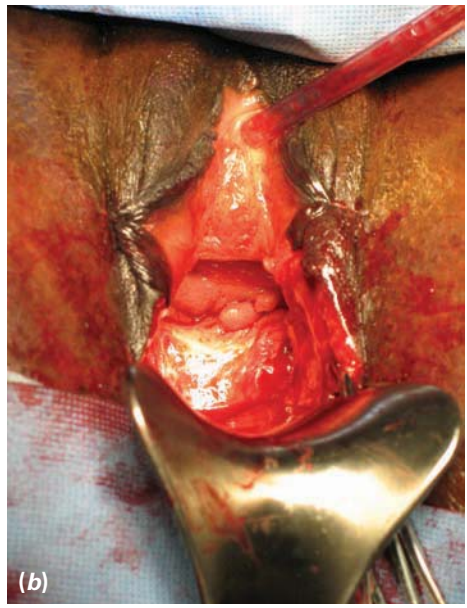

Figure 6.5 (*a, b*) Access has been improved by episiotomy.

Some surgeons infiltrate the vaginal wall around the fistula margin with a mild haemostatic agent (1:200 000 adrenaline (epinephrine)). This reduces blood loss, thus aiding dissection. There is a small risk of reactionary haemorrhage when the effect wears off. Others prefer isotonic saline. If the infiltrate is being introduced into the correct tissue plane beneath the vaginal skin, it should be introduced easily (except when there is severe scarring). Although many surgeons do not infiltrate at all, we believe that it is helpful for beginners.

Initially, the vaginal wall distal to the fistula should be held with the Allis forceps. Upward traction brings the fistula into view (Figure 6.6).

The proximal margin of the fistula is incised, with the incision being made through the full thickness of the vaginal wall, but not into the bladder. The incision is

Figure 6.6 The fistula is brought into view by upward traction.

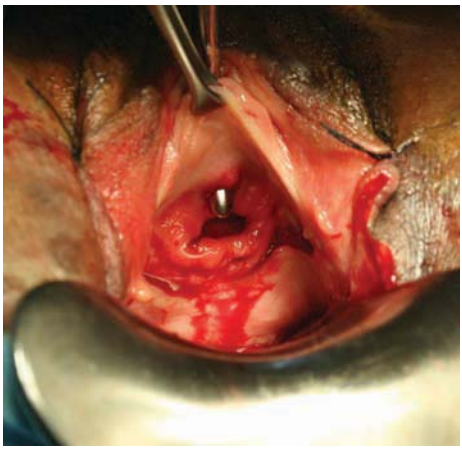

Figure 6.7 Access for dissection is facilitated by advancing the incision onto the lateral walls of the vagina.

advanced onto the lateral walls of the vagina from the left and right angles of the fistula. This assists with access for the dissection (Figure 6.7). A size 15 blade is most suitable for this step.

The proximal bladder wall is grasped with the Allis forceps and held by the assistant. The surgeon holds the vaginal wall with dissecting forceps and gently applies counter-traction to expose the operative plane. A combination of sharp and blunt dissection (Figure 6.8) is used to develop the plane between the bladder and the vagina. Note that the bladder and vagina are held apart with the Allis forceps to show the space between them. Opening the tips of scissors in this plane helps to develop it. Tension should be maintained on both the bladder and vaginal walls during dissection. It is important to stay just under the vagina. Bleeding is a warning that the bladder wall has been entered.

The dissection is extended laterally until the angles of the fistula are free. The dissection can appear rather extensive to the novice fistula surgeon, but it must be

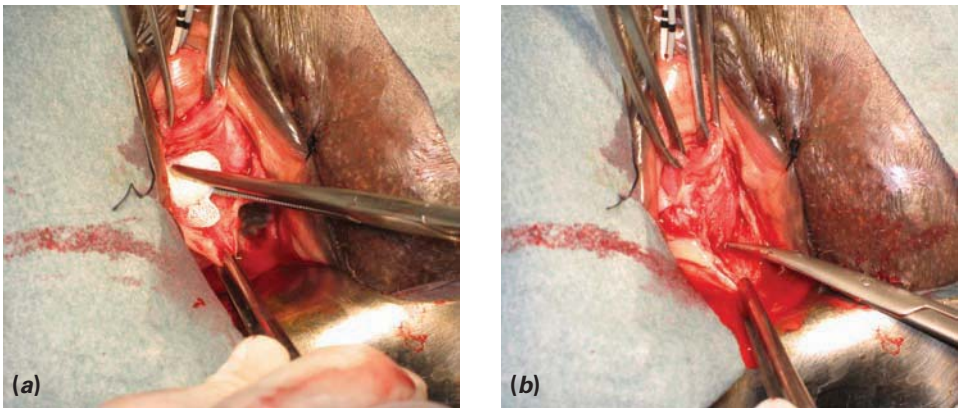

Figure 6.8 (*a, b*) The plane between the bladder and vagina is developed using a combination of sharp and blunt dissection.

extensive enough to free the bladder off the vagina to enable a completely tension-free closure of the bladder. Much more dissection will be done in a proximal direction, up to or beyond the cervix, than over the urethra, which is fixed. *This is the most crucial lesson for the fistula surgeon. If the bladder is closed under any tension, the operation will fail.*

In more severe injuries, the lateral margin of the fistula is the pubic bone, and clearly a different strategy is required. Management of this situation is discussed in 'Circumferential fistulae' later in this chapter.

Protection of ureters

It is wise to identify the ureters in all cases except for the very smallest fistulae. The ureters enter the bladder just distal to the level of the cervix and are indentified with a ureteric probe (Figure 6.9). (If the ureters are difficult to identify, 20 mg intravenous furosemide and a bolus of intravenous fluid will produce an intermittent spurt of urine from each ureteric orifice, aiding localization.) If the ureters are close to the fistula margin, they should be catheterized, advancing the catheters up to the renal pelvis and then withdrawing them slightly. This is done to avoid incorporating the ureters in the repair (even so, ureters have been injured during dissection – see Chapter 13). The catheters are brought out through the urethra by either threading them into a metal catheter or pulling them through with a small curved artery forceps (Figure 6.10). They are then secured onto the mons pubis with a simple stitch. Wherever possible, it is best to catheterize the ureters before beginning dissection.

After the proximal margin has been mobilized sufficiently, attention is given to the distal margin. Most surgeons new to fistula surgery find this plane difficult to dissect, especially when the fistula is pulled up behind the symphysis.

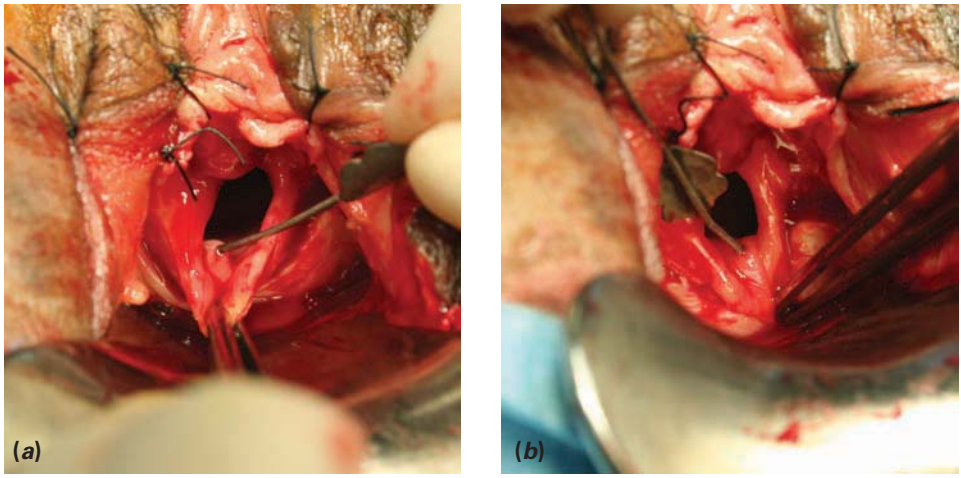

Figure 6.9 (*a*) Right ureteric orifice identified. (*b*) Left ureteric orifice identified.

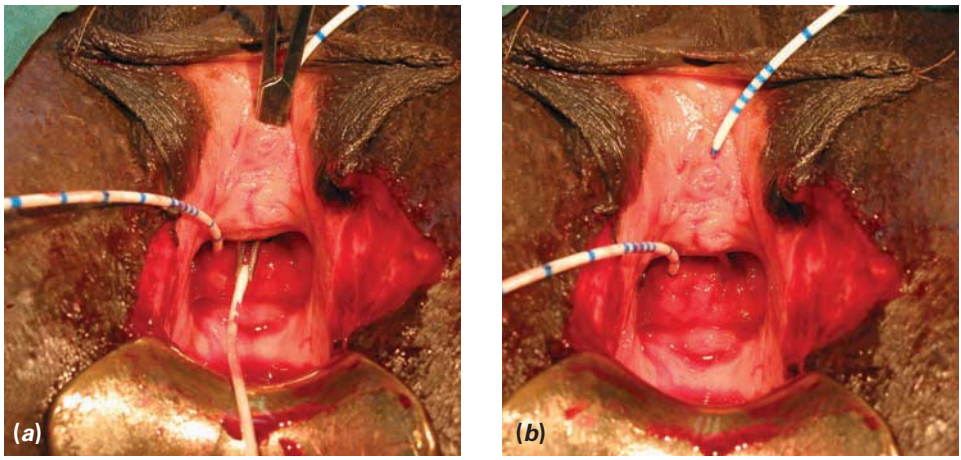

Figure 6.10 (*a, b*) Ureteric catheters are pulled through the urethra. In a case like this, they would be removed at the end of the operation.

The metal catheter is a useful retractor in the urethra, and it also helps the surgeon to gauge the thickness of the tissue planes, which are thin when approaching the urethra. To help with this, a small vertical incision may be made from the upper margin of the fistula distally in the midline. The incision around the distal fistula margin joins the previous proximal dissection. A lateral extension is made down the axis of the vagina. This may have already been done from the lateral ends of the proximal dissection. This is particularly important when a fistula is pulled up behind the symphysis.

The distal flap must now be dissected off the proximal urethra and para-urethral region. The elevation of the distal flap should always commence with dissection at its lateral edge (Figure 6.11), working towards the midline and repeating the same step on the other side. If this is not done, the urethra can easily be damaged and the flap torn. If the fistula is pulled up behind the symphysis, the right-angled tips of the Thorek scissors (see Chapter 5) are most helpful. The Allis forceps are again useful in providing traction to bring the upper margin into view and in providing traction and counter-traction to find the correct tissue plane.

When the surgeon judges that there has been enough dissection to enable a tension-free closure, the reflected tissue is sewn to the labia on each side with a suture (Figure 6.12).

The fistula edge is trimmed of any scar tissue or residual vaginal skin. The angles are examined again to ensure that they are not tethered to the inferior pubic ramus on either side. If so, further dissection is needed.

The fistula is then repaired with interrupted 00 absorbable sutures. The vagina is a confined area in which to operate, and suturing can pose a problem. Small, strong needles are needed. Fish-hook (J) needles or 5/8-circle needles are ideal. The angles are secured first, taking bites distal, proximal and lateral to the fistula angle. The

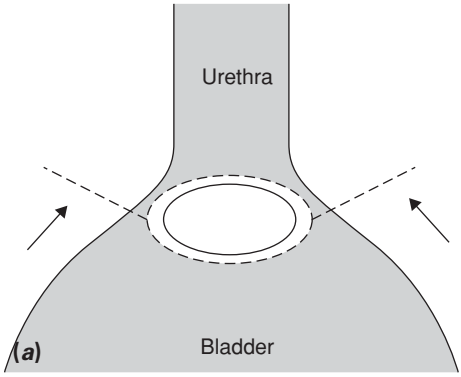

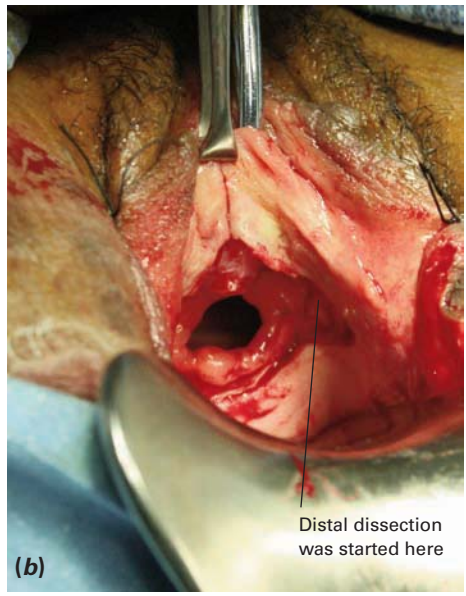

Figure 6.11 (*a*) To elevate the distal flap, the dissection is always started laterally, working towards the urethra from both sides. (*b*) Distal dissection. Note that a small vertical incision has been made though the vaginal skin over the urethra. This is optional.

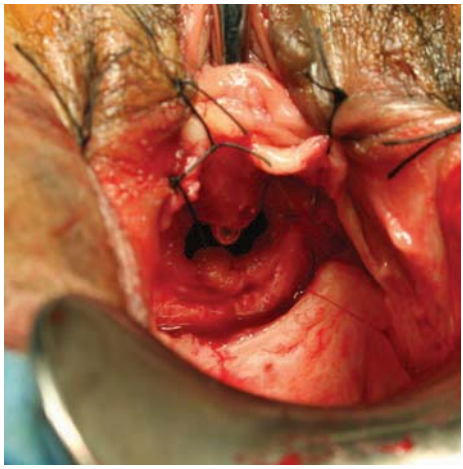

Figure 6.12 The distal flaps have been sutured up out of the way. The extent of dissection can be seen. Note the metal catheter in the urethra.

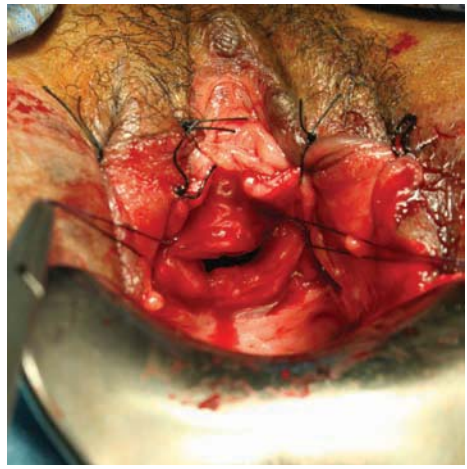

Figure 6.13 The two corner sutures have been inserted and held.

corner sutures are clipped after tying for identification (Figure 6.13). For the central sutures, it may be easier if they are not tied until all have been inserted.

It is very important to ensure that there is no protrusion of bladder mucosa at any point along the suture line. This is especially so at the corners. The suture includes only the bladder muscle; the mucosa is excluded from the repair so as to invert it into the bladder (Figure 6.14).

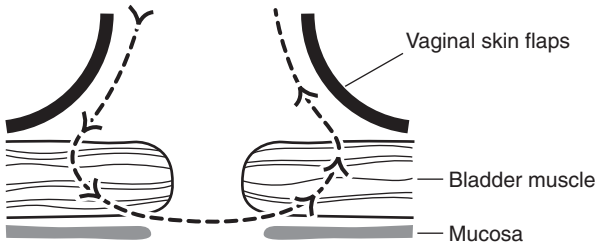

Figure 6.14 The suture includes only the bladder muscle, avoiding the mucosa.

One layer or two?

Traditionally, two layers have been recommended, but there are many surgeons (including ourselves) who use only one layer as a general rule. The bites must be accurately and evenly spaced. One technical tip is never to try to hold forceps and needle holder while tying knots. It is much easier to judge tension accurately when both hands are free (Figure 6.15). A second layer should never be used when suturing to proximal urethra. There is a high chance that this would cut out or effectively shorten the urethra. However, in other situations when there is available tissue, we do recommend that beginners add a second layer.

Once the repair has been completed (Figure 6.16), a dye test is performed to ensure sound closure of the bladder (Figure 6.17). A no. 16 Foley catheter is passed, saline coloured with methylene blue is introduced into the bladder (around 100 cm^3 should suffice) and the suture line is checked for leaks. A common error is to use the dye too concentrated. Leakage from the repair or urethra will stain everything too much, making identification of the leak difficult.

Figure 6.15 Both hands should be free of instruments while tying knots.

Figure 6.16 Completed repair.

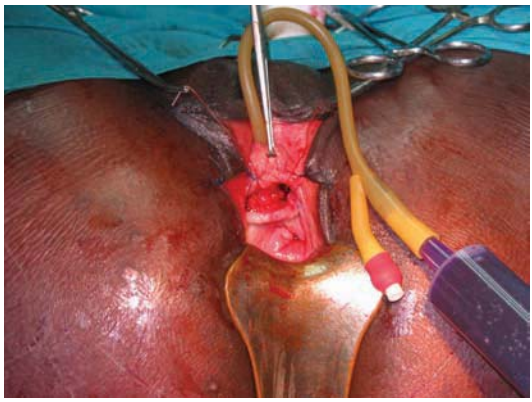

Figure 6.17 A dye test in progress.

A more objective method is to fill the bladder via a filter funnel or open syringe, pouring in the dye until the intravesical pressure is about 30 cmH_2O. This is judged by the height of the fluid in the vertically held catheter. The volume instilled gives a measure of the functional capacity of the bladder.

A patient may have more than one fistula, so it is important to inspect the rest of the vagina carefully for leaks. It may be necessary to gently press on the urethral meatus with a swab to prevent dye leaking out of the urethra and spilling into the vagina, making interpretation of the test difficult. If the dye test is satisfactory, pressure over the urethra can be released to look for a urethral leak. Whether this predicts stress incontinence remains to be determined.

Sometimes, an additional suture is required, but, if the leak is not controlled by one or two additional sutures, it is better to take at least part of the repair down and begin again rather than inserting more and more sutures that will only strangle tissue.

Vaginal closure

This is performed with interrupted sutures (Figure 6.18). It is usual to close the vagina completely where possible, but, if there has been a more extensive dissection or there is marked loss of vaginal tissue, it is may be better to leave some gaps. If the vaginal incision is closed tightly after a large dissection, an infected haematoma could burst into the bladder and/or the vagina, whereas, if the vagina is partly open, blood or infection can readily drain out.

Haemostasis

Actively bleeding vessels should always be secured by an under-running suture, but sometimes a degree of continuous oozing has to be accepted. This may be reduced by greater head-down tilt or dilute adrenaline-soaked swabs, and finally controlled by packing.

Figure 6.18 The vaginal skin has been closed with a mattress suture.

Figure 6.19 The repair should be protected with a Sims speculum when inserting the pack.

Vaginal packing

It is traditional to finish by packing the vagina with gauze soaked in antiseptic solution. However, this may not be necessary. Residual venous oozing is common at the end of large cases, and a firm pack may stop this. It is important to realize, however, that a pack may prevent the recognition of serious bleeding for several hours. There is probably no need to pack in most simple dry cases, but, to simplify nursing, it is better to have an 'all-or-none' policy, as a retained pack is a disaster. We still prefer a pack for all cases, with its removal the next day.

When packing, the site of the repair should always be protected with a Sims speculum (Figure 6.19).

Securing the indwelling catheter

Some surgeons prefer to suture the indwelling catheter onto the labia whereas others just tape the catheter (see Chapter 11). The aim is to ensure that the balloon

of the catheter does not put pressure on the repair site. This should not be a problem for high vaginal fistulae, where the repair site is away from the bladder neck, but, for those fistulae involving the urethra or bladder neck, we prefer to suture the catheter in place to prevent any pressure or traction on the repair. The important thing to remember is to keep the bladder empty with the catheter draining well during the 2 weeks after the operation.

The next section describes the selection of cases for a beginner, with the more challenging fistulae being described in subsequent sections.

SELECTION OF CASES FOR THE BEGINNER

We shall repeatedly emphasize that selection of cases is the most important aspect of fistula management that a trainee must learn.

It must be remembered that to attempt a case beyond one's capabilities is not only demoralizing for the surgeon but a disaster for the patient, as the best chance of cure is always the first operation.

Of all the new cases presenting, only about one-quarter will be suitable for a beginner. History taking does not help that much in selecting the easy ones. A small hole leaks just as much as a big one.

There are some clues that should make one suspicious of a serious or difficult fistula:

- Neurological weakness (usually foot drop), even if it has recovered, suggests a difficult case.
- Rectal fistulae usually occur in association with a serious bladder injury. This does not apply to anal sphincter injuries, which often occur in isolation.
- Fistulae following caesarean section are often in the region of the cervix and therefore high.
- A fistula following hysterectomy for a ruptured uterus will usually be in the vault or be due to an accidental ureteric injury.

The only clue to a potentially easy case is when a patient gives a history of pregnancies in spite of having a fistula. Clearly, there cannot have been too much damage to the genital tract. About 10% of our cases have had pregnancies while suffering from a fistula.

Examination is the key to selection. The features to look for are:

- a vagina without shortening or stenosis
- a fistula that is easily palpable or visible, and that is small, soft and accessible, but not too close to the cervix or to the external urethral orifice.

There is no need to examine such a patient under anaesthesia. If the fistula cannot be easily seen in the conscious patient using a Sims speculum then it is not a simple case.

In summary, novice surgeons should confine themselves to:

- small fistulae not involving the urethra
- those with minimal scar
- those that are easily accessible.

An ideal case

Unfortunately, only 10% of cases are as easy as the one shown in Figure 6.20.

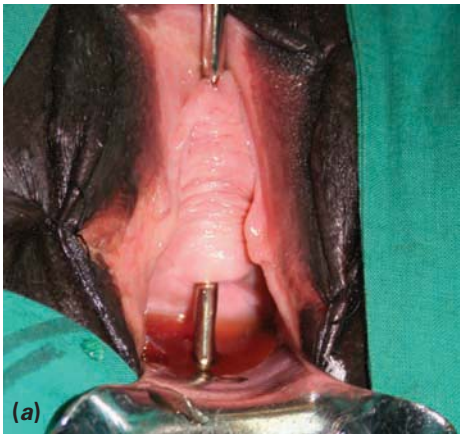

Figure 6.20 (*a*) A small mid-vaginal fistula (Goh's type 1al). (*b*) The distal wall of the vagina is held up with Allis forceps to expose the fistula. It is seen well distal to the cervix.

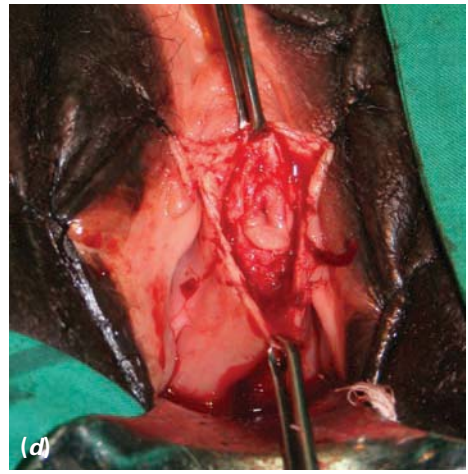

(*c*) Incision around the fistula. (*d*) Extent of mobilization. The bladder margin will be trimmed of vaginal mucosa and inverted with one layer of sutures, taking good bites of bladder proximal and distal to the defect.

(*continued*)

Figure 6.20 (*e*) The vagina is closed over the repaired bladder.

Some relatively easy cases

Some other examples of cases suitable for a trainee are shown in Figures 6.21–6.25.

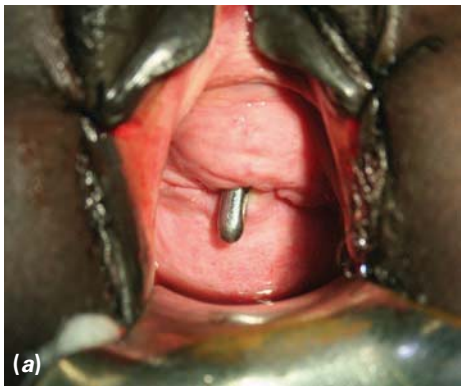

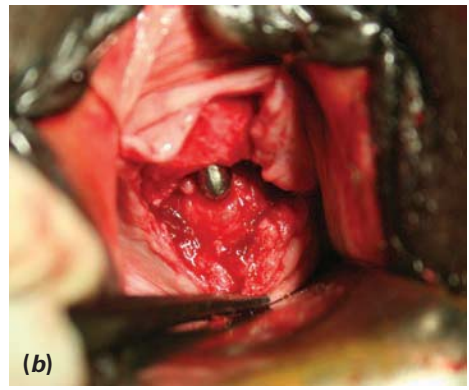

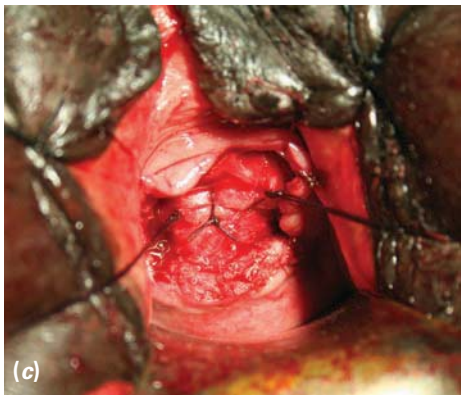

Figure 6.21 (*a*) A simple mid-vaginal fistula (Goh's type 1al). (*b*) The extent of dissection. (*c*) Closure in one layer.

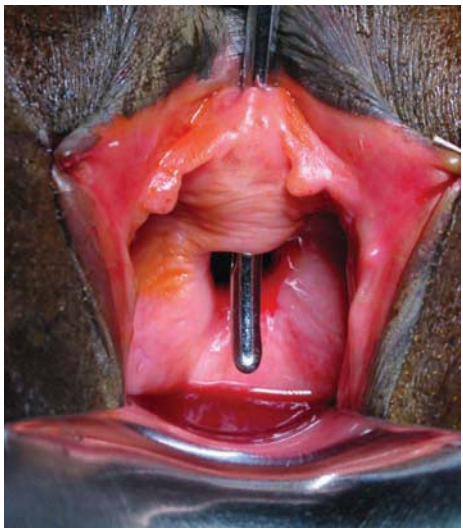

Figure 6.22 A medium-size fistula at the junction of the urethra and bladder. The margins of the fistula are soft and are clearly seen. The urethra is just intact (Goh's type 2bI).

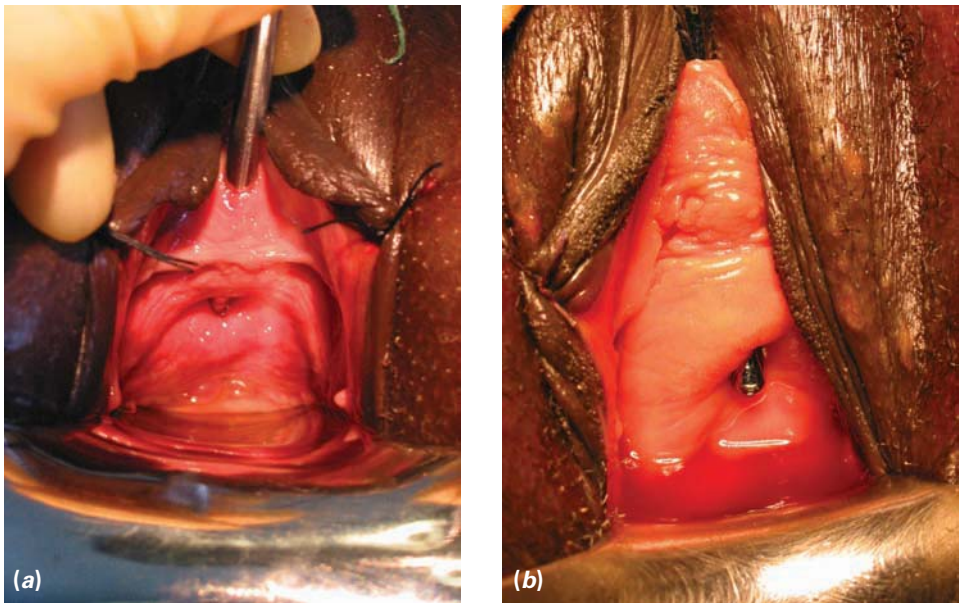

Figure 6.23 Two simple fistulae. Note that the fistula in (*a*) is not as accessible as that in (*b*). The former will become much easier after an episiotomy.

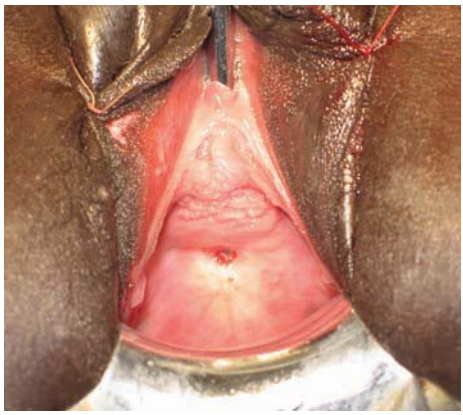

Figure 6.24 The hole in this case appears tiny, but there is considerable fibrosis around it. The scar tissue must be excised, so a generous mobilization will be required to reach healthy bladder.

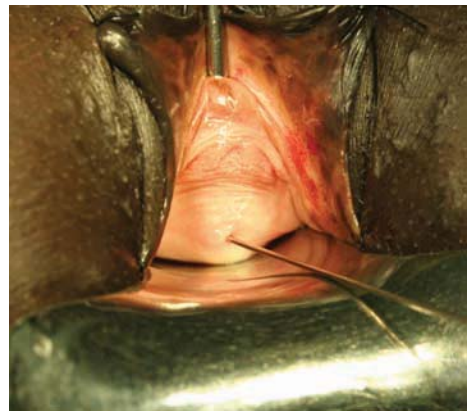

Figure 6.25 This pinhole fistula is easy to see, but can be quite troublesome to close. The probe should be kept in the fistula during the dissection, otherwise the track may be lost.

Some difficult cases

The cases shown in Figures 6.26–6.29 are more difficult, and should not be attempted by a beginner.

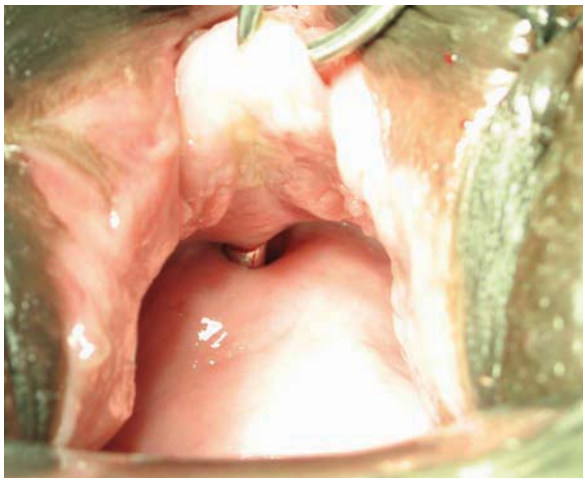

Figure 6.26 This juxta-urethral fistula is pulled up behind the symphysis, making access difficult. There is also almost complete separation of urethra and bladder (Goh's type 2aIII).

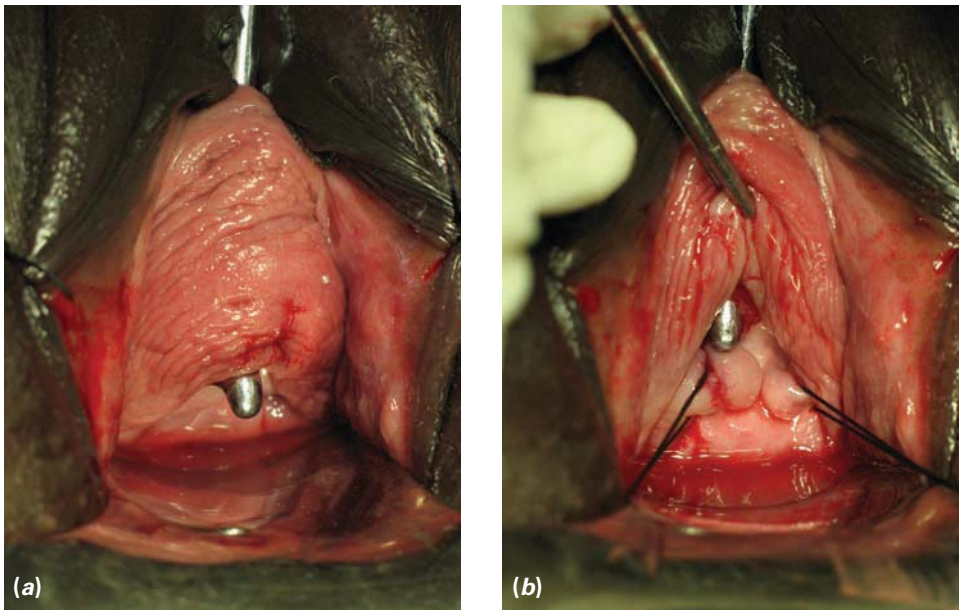

Figure 6.27 (*a, b*) This juxta-cervical fistula opens high into an open cervical canal. It is a challenging case to repair, but has an excellent prognosis because the urethro-vesical junction is undamaged.

Figure 6.28 The defect in the vagina here is so large that the bladder has prolapsed, but this is perfectly curable by a regular fistula surgeon.

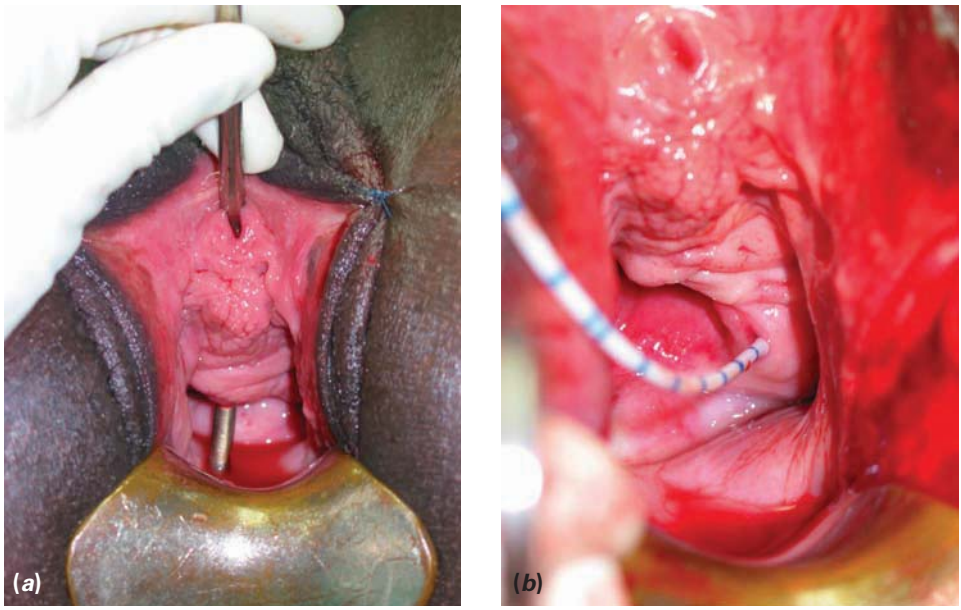

Figure 6.29 (*a,b*) This is a large fistula high in the vagina and involving the cervix (Goh's type 1cIII). When fully exposed after an episiotomy, the ureteric orifice is seen on the edge of the fistula. This would be quite easy for an expert, but a novice could get into difficulty.

JUXTA-URETHRAL AND CIRCUMFERENTIAL FISTULAE

The following are discussed in this section:

- Management of juxta-urethral and circumferential fistulae
- Management of ureteric involvement.

The key to repair of the more complex fistulae is to understand the circumferential fistula.

Anyone reading standard textbook accounts of vesico-vaginal fistula repair may get the impression that the fistula is simply a hole in the base of the bladder that needs to be closed transversely in one or two layers. The concept of circumferential loss and the strategies for dealing with this are often glossed over.

In the majority of cases, the ischaemic injury occurs at the urethro-vesical junction. When there is complete separation of urethra and bladder, the defect is called circumferential. If the urethra and bladder are still together to some extent, the defect is, by tradition, called juxta-urethral.

The degrees of circumferential loss are illustrated in Figure 6.30. It must be appreciated that in the larger defects the antero-lateral bladder wall is adherent to the pubic rami. The practical point is to make the distinction between fistulae with a