

8 REPAIR OF ANAL SPHINCTER INJURIES

Immediate repair

Anal sphincter tears seen within 24 hours of delivery should be repaired at once. This is not a minor operation. The patient's future continence depends on the skill of the repair.

It is important when carrying out the repair to realize that torn anal sphincters retract to the 3 and 9 o'clock position.

The repair must be carried out in an operating theatre with good lighting, instruments and assistance. Repair under local anaesthesia is possible, but it is better to have the patient under a spinal or general anaesthetic. The patient should come to theatre with an empty rectum.

The ano-rectal mucosa are closed first; then the torn ends of the external sphincter are identified (the internal sphincter cannot be identified as a separate layer). These ends are sutured accurately, taking quite big bites using a slowly absorbable suture (Vicryl or Dexon). Three to four sutures are needed. The vagina and perineal skin are then closed, using good mattress sutures to build up the perineal body.

Secondary repair

If the repair cannot be performed immediately, it is best to wait for several weeks. Sometimes, patients with an old complete tear say that they have no symptoms, so it is important to be sure that a patient really does have troublesome faecal leakage before recommending repair. In the best hands, only 80% of repairs restore complete continence.

Again, it is important to realize that the torn ends of the sphincter have retracted round half the anal circumference, and simply freshening the margins of the tear and suturing them is unlikely to give a good result. The procedure is illustrated in Figure 8.1.

The patient is usually kept on fluids only for the first two postoperative days. A mild laxative can be given on the third day.

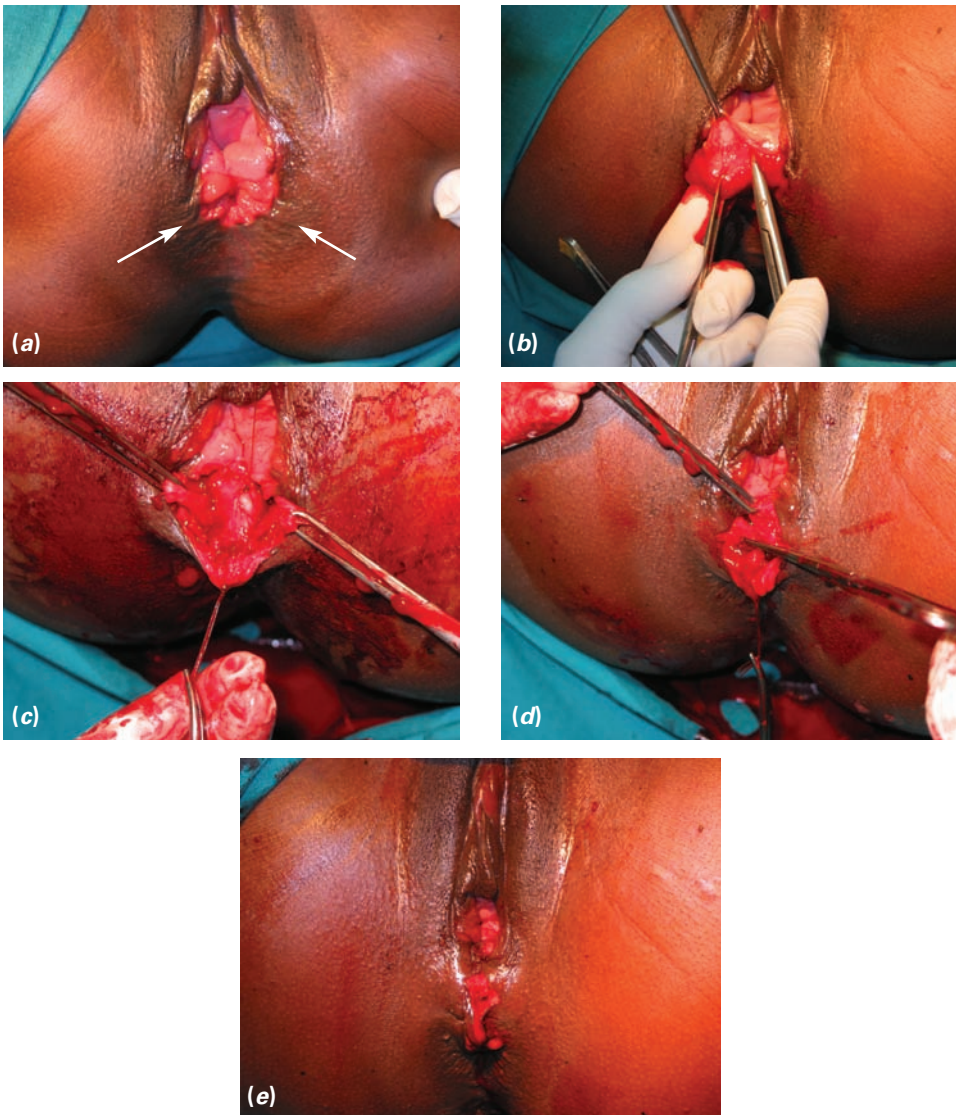


Figure 8.1 (a) A late complete anal sphincter tear. The arrows indicate the position of the retracted sphincter ends. (b) The vaginal mucosa is separated from the rectal mucosa well above the tear. Then the ends of the sphincter are identified postero-laterally. A block of tissue that contains the sphincter end should be mobilized. If only muscle is mobilized, it will easily tear. (c) The ano-rectal mucosa has been repaired, and blocks of tissue containing the external sphincter are held in forceps. (d) The aim is to repair the sphincters by overlapping the two blocks of tissue. The mobilized tissue should contain some scar tissue around the sphincter. Pure sphincter muscle would not hold sutures well. (e) The completed repair. The initial transverse incision has been converted to a vertical one. There is tension in the middle of the suture line, so the wound has been left open here. Should infection or bleeding occur, the repair would not be compromised.